This is a digital copy of a book that was preserved for generations on library shelves before it was carefully scanned by Google as part of a project to make the world's books discoverable online.

It has survived long enough for the copyright to expire and the book to enter the public domain. A public domain book is one that was never subject to copyright or whose legal copyright term has expired. Whether a book is in the public domain may vary country to country. Public domain books are our gateways to the past, representing a wealth of history, culture and knowledge that's often difficult to discover.

Marks, notations and other marginalia present in the original volume will appear in this file - a reminder of this book's long journey from the publisher to a library and finally to you.

Usage guidelines

Google is proud to partner with libraries to digitize public domain materials and make them widely accessible. Public domain books belong to the public and we are merely their custodians. Nevertheless, this work is expensive, so in order to keep providing this resource, we have taken steps to prevent abuse by commercial parties, including placing technical restrictions on automated querying.

We also ask that you:

+ *Make non-commercial use of the files* We designed Google Book Search for use by individuals, and we request that you use these files for personal, non-commercial purposes.

+ *Refrain from automated querying* Do not send automated queries of any sort to Google's system: If you are conducting research on machine translation, optical character recognition or other areas where access to a large amount of text is helpful, please contact us. We encourage the use of public domain materials for these purposes and may be able to help.

+ *Maintain attribution* The Google "watermark" you see on each file is essential for informing people about this project and helping them find additional materials through Google Book Search. Please do not remove it.

+ *Keep it legal* Whatever your use, remember that you are responsible for ensuring that what you are doing is legal. Do not assume that just because we believe a book is in the public domain for users in the United States, that the work is also in the public domain for users in other countries. Whether a book is still in copyright varies from country to country, and we can't offer guidance on whether any specific use of any specific book is allowed. Please do not assume that a book's appearance in Google Book Search means it can be used in any manner anywhere in the world. Copyright infringement liability can be quite severe.

About Google Book Search

Google's mission is to organize the world's information and to make it universally accessible and useful. Google Book Search helps readers discover the world's books while helping authors and publishers reach new audiences. You can search through the full text of this book on the web at `http://books.google.com/`

LANE MEDICAL LIBRARY STANFORD
2 45 0423 0854

D1673
E65m
1880
Atlas

ATLAS

OF

MEMOIR UPON THE UTRICULAR GLANDS OF THE UTERUS AND THE GLANDULAR ORGAN OF NEW FORMATION WHICH IS DEVELOPED DURING PREGNANCY.

LANE LIBRARY

CONSISTING OF

TEN PLATES.

ALSO OF

MONOGRAPH UPON THE UNITY OF THE ANATOMICAL TYPE OF THE PLACENTA,

CONSISTING OF FIVE PLATES.

BY

PROFESSOR G. B. ERCOLANI,
OF BOLOGNA.

ENGRAVED BY BETTINI,

AND REPRODUCED BY THE HELIOTYPE PROCESS.

BOSTON:
HOUGHTON, OSGOOD AND COMPANY.
The Riverside Press, Cambridge.
1880.

D

LANE LIBRARY

Copyright, 1880,
By H. O. MARCY, M. D.

RIVERSIDE, CAMBRIDGE:
STEREOTYPED AND PRINTED BY
H. O. HOUGHTON AND COMPANY.

E65m
1880

EXPLANATION OF THE PLATES.

PLATE I.

THE four figures of this plate represent the plan of structure, and the relations of the two parts which constitute the Placenta, namely: the vascular or fœtal portion, and the glandular or maternal portion, in the mammiferous animals and in the human species.

FIGURE 1.

Disseminated or villous Placenta. The figure represents a vertical section of the uterus, placenta, and chorion of the mare.

(*a*) Chorion.

(*b*) Arterial and venous vessels, in connection with those of the umbilical cord, from which spring the villi constituting the fœtal portion of the placenta.

(*c*, *c*) The villi of the chorion.

(*d*, *d*) Simple and bilocular glandular follicles furnished with an internal epithelium; developed only during gestation over the whole internal uterine surface in the mare, and constituting the glandular or maternal portion of the placenta.

(*e*) Wall of the uterus.

(*f*, *f*) Sub-mucous connective tissue of the uterus which proliferates between the glandular follicles, and is traversed by the utero-placental vessels.

FIGURE 2.

Multiple Placenta. Diagram representing a vertical section of the uterus, a portion of a cotyledon, and of the chorion in the cow.

(*a*) Chorion.

(*b*) Arterial and venous vessels, in connection with those of the umbilical

cord, from which spring the villi constituting the fœtal cotyledons, or the fœtal portion of the placenta.

(*c*, *c*) The villi of the chorion.

(*d*, *d*) Aggregation of simple glandular follicles, furnished with internal epithelium, superimposed upon each other and opening into a common cavity, by which the vascular tufts of the villi of the chorion enter. The aggregation of follicles constitutes the uterine cotyledon, namely: the maternal or glandular portion of the placenta of this animal.

(*e*) Walls of the uterus.

(*f*) Peduncle of the cotyledon in the gravid uterus; the permanent or rudimentary cotyledon of the books in the non-gravid uterus.

(*g*, *g*) Connective tissue which rises from the rudimentary cotyledon, and proliferates between the follicles of the glandular organ of new formation; and in which circulate the vessels of the uterine cotyledon, or the utero-placental vessels of animals having a single placenta.

FIGURE 3.

Single Placenta in animals. This diagram represents a vertical section of the uterus, placenta, and chorion of a dog.

(*a*) Chorion adhering to the fœtal surface of the placenta.

(*b*) Arterial and venous vessels in connection with those of the umbilical cord, from which are developed the villi constituting the fœtal portion of the placenta.

(*c*, *c*) The villi.

(*d*, *d*) Glandular follicles, very sinuous in their course, and communicating with each other; the maternal portion of the placenta proceeding from the folds and the depressions preëxisting in the mucous membrane of the non-gravid uterus. The closed extremity of these follicles is indicated at the bottom by the letter *g*; at the top, the same letter indicates their orifice, which is adherent to the chorion.

(*e*, *e*) Walls of the uterus.

(*f*) Connective tissue which rises between the large folds of mucous membrane transformed into sinuous glandular follicles, traversed by the maternal or utero-placental vessels.

(*h*, *h*) Large festooned folds of the uterine mucous membrane at the external edges of the placenta; the fringes or internal festoons of these folds (*g*, *g*) are transformed into glandular follicles.

FIGURE 4.

Human Placenta. A vertical section of the uterus, placenta, and chorion is here represented, as in the preceding diagrams.

(*a*) Chorion adhering to the fœtal surface of the placenta.

(*b*) Arterial and venous vessels in connection with those of the umbilical cord, from which are given off the villi constituting the fœtal portion of the placenta.

(*c*, *c*) The same villi which are seen completely enveloped in a sheath (*d*, *d*) from the chorion to the uterus.

(*d*, *d*) The sheath which originates in the decidua serotina, and is composed of an external wall and an internal epithelial layer which constitute the glandular organ or maternal portion of the placenta.

(*e*, *e*) Walls of the uterus.

(*f*) Decidua serotina which covers the uterine surface of the placenta.

(*g*) Transformation of the walls of the glandular organ furnished to the villi by the serotina into fibrous tissue, so as to fasten firmly to the chorion the vessels of the fœtal portion of the placenta.

(*h*) A villus of the fœtal placenta from which has been removed the outer envelope furnished by the serotina, and which forms the maternal placenta.

PLATE II.

FIGURE 1.

Represents a fold of the uterine mucous membrane of a dog at the end of gestation, placed on a slide, and magnified 250 diameters. The epithelium has been mostly removed to exhibit a utricular or branching gland of the uterus, and to show that there does not exist another species of glands called simple by way of distinction.

(*a*) Utricular or branching gland diminished in length by a blank space across the figure.

(*b*) Rounded orifice of one of these glands, seen from the front, opening into the cavity of the uterus. The tunnel shape of these glands near their opening is clearly seen at *a*. In this portion of the mucous membrane, where is represented the mouth of the utricular glands in the uterus, all of the epithelium has not been removed, and we see the manner in which it is disposed in layers at *c*, *c*.

(*d*, *d*, *d*) Sub-mucous vascular net-work in which is very distinctly seen the formation of new vessels by means of the corpuscles of connective tissue. In many places it is impossible to decide whether the corpuscle is or is not already transformed into a vessel.

FIGURE 2.

Portions of a utricular gland of the uterus of a cow magnified 200 diameters, to give an idea of the goitre-like forms and the appendages belonging to these glands in that animal. The figure plainly shows the external membrane and the internal cylindrical epithelium of these glands.

(*b*, *b*) Goitre-like appendages.

(*c*) Termination, ordinarily bilocular, of these glands in the cow.

PLATE III.

The mucous membrane of the gravid and the non-gravid uterus of the mare magnified only 25 diameters.

FIGURE 1.

Vertical section of the mucous membrane of the non-gravid uterus.

(*a*, *a*) Epithelium of the internal surface of the uterus designated by a dark line. The slight enlargement does not show the epithelial elements of which it is composed.

(*b*, *b*) Simple utricular glands of irregularly sinuous course, some of which are whole, others cut in different directions.

FIGURE 2.

The same section in the gravid uterus at the end of gestation, equally magnified.

(*a*, *a*, *a*) Glandular follicles which, instead of the epithelium, line the whole internal surface of the gravid uterus.

(*b*, *b*) Openings of the utricular glands into the uterine cavity. These are seen below, cut in different ways.

FIGURE 3.

Vertical section of the uterine mucous membrane of a non-gravid mare, magnified 250 diameters.

(*a*, *a*) Superficial layer of the ciliated epithelium of the internal uterine cavity,

and deep layers proceeding from a transformation of the corpuscles of the connective tissue.

(*b*, *b*, *b*) Opening of the utricular glands amidst the layers of the epithelium.

(*c*, *c*, *c*) The same glands, lower down, cut transversely amidst the sub-mucous connective tissue.

PLATE IV.

Vertical section of the chorion and the placenta of the mare, magnified 250 diameters.

FIGURE 1.

(*a*) Chorion.

(*b*) Epithelial layer which covers the uterine face of the chorion, and which may be considered as representing the decidua vera in this animal.

(*c*) Arterial and venous vessels in connection with the umbilical cord. In the chorion many are shown cut transversely. From these vessels issue in the form of tufts the numerous ramifications which constitute the chorial villi or the fœtal portion of the placenta.

(*d*, *d*) Two of these villi covered with their external epithelium.

(*e*) Another villus which shows in its interior the vascular loop.

(*f*, *f*) Roots of cut villi.

(*g*, *g*) One of the innumerable glandular follicles from which the glandular or maternal portion of the placenta in this animal is formed. It contains a villus of the chorion, shaded darker in the figure.

(*h*) Another of these follicles, the upper third part cut off, and the villus of its internal cavity removed. Here are more readily seen both the exterior membrane and the internal epithelium of the follicle.

(*i*) Tunnel-shaped opening of a glandular follicle through which enters the corresponding villus of the chorion.

(*l*, *l*) The utero-placental vessels which form as many looped tufts within the connective tissue that rises between the glandular follicles.

(*m*, *m*) Lateral branches of these vessels which form a rich vascular net-work around the glandular follicles.

FIGURE 2.

Utricular glands from the gravid uterus of the cat almost at term. Their different sizes show that they may greatly vary in volume, but that in this animal, also, there do not exist two species of uterine glands.

(*a*) Tunnel-shaped opening, or mouth of the foregoing.

(*b*, *b*) Closed extremity of the glands.

(*c*) Epithelial layers of the uterine mucous membrane. There are still larger utricular glands, not here represented, in the closed extremity of which are sometimes found a variety of compartments.

PLATE V.

FIGURE 1.

Section, in part transverse, in part oblique, of the glandular organ or maternal portion of the Placenta, which is developed over the whole internal surface of the uterus in the gestation of the mare, enlarged 250 diameters.

(*a*, *a*) Glandular follicles cut obliquely towards their closed extremity.

(*b*, *b*) The same cut transversely.

(*c*, *c*) Connective tissue of the uterus, which rises between the glandular follicles, and in which course the utero-placental vessels.

(*d*) One of the above-named vessels.

(*e*, *e*) Portions of the parietal, vascular net-work formed about the follicles by the vessels aforesaid.

(*f*, *f*) Two utricular glands rising within the connective tissue of new formation of the uterus, and emptying, as in the non-gravid uterus, into the internal uterine cavity. In the figure they are cut transversely towards the base of the glandular follicles.

FIGURE 2.

Transverse section of the mucous membrane covering the rudimentary cotyledons of the non-gravid uterus of a cow, magnified 250 diameters, to show that in the uterus of the cow there really exist two species of uterine glands.

(*a*, *a*) Two utricular glands cut transversely, which appear surrounded by a very great number of small glandular follicles varying in size.

PLATE VI.

FIGURE 1.

Vertical section of a part of the cotyledon of the gravid uterus of the cow, showing the relations of the fœtal and the uterine placentæ, enlarged 250 diameters.

(*a*, *a*, *a*) Vessels of the fœtal placenta forming the vascular tufts known by the name of fœtal cotyledons.

(*b*, *b*, *b*) (*c*, *c*, *c*) Glandular follicles superimposed upon each other, and constituting the maternal portion of the placenta or the uterine cotyledon. With a vertical incision the follicles are necessarily cut in different directions; in *c*, *c*, *c* are shown incisions more or less transversal; in *b*, *b*, *b* the section of the follicle is, in part, vertical, showing its shape and arrangement.

(*d*, *d*) Connective tissue which, rising from the surface of the permanent uterine cotyledons, and insinuating itself between follicle and follicle, constitutes the stroma of the new glandular organ. Between the laminæ of this connective tissue run the nutritive maternal vessels corresponding to the utero-placental vessels.

(*e*, *e*, *e*) Connective tissue of the peduncle of the cotyledons formed from the rudimentary or permanent portion of the cotyledons of the non-gravid uterus.

(*f*, *f*) Transverse section of two nutritive or uterine arteries of the uterine cotyledon.

(*h*) Transverse section of a portion only of a uterine vein of the cotyledon.

(*m*, *m*) Two glandular follicles, one cut transversely, the other in part longitudinally. In the interior of the latter are seen certain cells very different from the simple epithelial ones that clothe the internal surface of the same follicles in the non-gravid uterus. (See Plate V., Fig. 2.)

PLATE VII.

Formation of the single Placenta in the rabbit, enlarged 250 diameters.

FIGURE 1.

Vertical section of the mucous membrane of the uterus of a rabbit between the eighth and the tenth days of gestation. The preparation was taken from the mucous membrane near the placenta.

(*a*, *a*) Normal follicles of the mucous membrane enormously enlarged. The lower wall of these follicles has been cut in a few of them. See *b*.

(*c*) Some of the same follicles included in the vertical incision, and cut transversely towards their base.

(*d*, *d*) Sub-mucous connective tissue of the uterus in course of proliferation.

FIGURE 2.

Transverse section of the young Placenta towards the uterine surface, to show at *a*, *a* how very quickly the aforesaid follicles expand tunnel-wise at the place where the placenta is formed.

(*b*) Two of these follicles very near together, and united at their base.

(*c*, *c*) Hyperplasic and hypertrophic connective tissue proceeding from the connective tissue of the uterus, which is to undergo further changes in proportion as the placenta develops.

FIGURE 3.

Transverse section of the same Placenta towards its fœtal surface.

(*a*, *a*) Represents in course of formation glandular tubes destined to receive the vascular villi of the chorion.

(*c*, *c*) Connective tissue as in Fig. 2, *c*.

FIGURE 4.

Vertical section of a fold of the mucous membrane from the same uterus of the rabbit, but somewhat farther from the place where the placenta begins to form.

(*a*) Uterine connective tissue.

(*b*, *b*) The same raised by proliferation, thus increasing in volume the folds of the mucous membrane and its numerous festoons.

(*c*, *c*, *c*) Openings made by the incision of the aforesaid festoons, cup-shaped and much enlarged.

(*d*, *d*) Small follicles of the mucous membrane cut towards their base.

(*e*) A sub-mucous vessel which would have become utero-placental if this fold had been changed into the maternal portion of the placenta.

This elegant structure of the folds of the mucous membrane at a distance from the point where the ovum is arrested gives an idea of the primitive structure of the maternal placenta at the place where the ovum is arrested.

PLATES VIII. AND IX.

These two plates represent a complete vertical section of the Placenta of the dog at the end of gestation, enlarged 250 diameters.

PLATE VIII.

Fœtal surface of the Placenta.

FIGURE 1.

(*a*, *a*) Chorion: its cells of connective tissue are blended with those cells of connective tissue originating from the uterus by which the chorion adheres firmly to the fœtal surface of the placenta.

(*b*, *b*) Vessels in connection with those of the umbilical cord, from which originate the villi constituting the fœtal portion of the placenta, which enter into the glandular follicles.

(*c*, *c*) The openings of the glandular follicles upon the fœtal surface of the placenta, having numerous intercommunications by means of short tubes (*d*).

(*d*) Short tube of communication, whole.

(*e*, *e*) Openings made by the section of as many of these tubes of intercommunication.

(*f*, *f*) Connective tissue proliferated from that of the uterus, and traversed by the utero-placental vessels.

(*g*, *g*) The vessels aforesaid.

FIGURE 2.

Middle portion of the same Placenta, to show the exceedingly sinuous course of the glandular follicles, seen entire in places designated by the letter *a*, and half open at *b*. The letters *e*, *f*, *g* correspond to the parts indicated by the same letters in the preceding figure.

PLATE IX.

Uterine portion of the same Placenta.

(*a*, *a*) Uterine connective tissue.

(*b*, *b*) Utricular glands cut transversely.

(*c*, *c*) Connective tissue which has proliferated between the great folds and festoons of the mucous membrane transformed into glandular follicles.

(*d*, *d*, *d*) Closed extremities (*culs-de-sac*) of the glandular follicles formed by the festoons of the mucous membrane, into the lowest cavity of which the villi of the fœtal placenta do not penetrate.

(*e*, *e*, *e*) Openings into the *culs-de-sac* of the said glandular follicles of the sinuous tubes, within which are found only the villi of the fœtal placenta. See Plate VIII., Fig. 2, *a*, *b*.

PLATE X.

Human Placenta enlarged 250 diameters.

FIGURE 1.

Vertical section of the Placenta at its fœtal surface.

(*a*) Chorion: its cells of connective tissue are blended with the cells of the serotina having become fibrous.

(*b*, *b*) Arterial and venous vessels connected with those of the umbilical cord, from which are derived the villi constituting the fœtal portion of the placenta.

(*c*, *c*) Semi-fibrous layer of the serotina adhering to the chorion, in the midst of which are seen some cells of the serotina not yet transformed into fibrous cells.

(*d*, *d*) Vessels of the villi cut transversely and contained in the glandular organ, the external wall of which is thicker near the chorion.

(*e*, *e*) Walls of the glandular organ changed into a fibrous cord round vessels of the villi near the chorion.

(*f*, *f*) Thick cells and loose connective tissue of the serotina in relation of continuity with that of the uterus.

(*h*) The same cells of the serotina changed into fibrous tissue, limiting the sinuses of the placenta.

(*g*, *g*) Sinuses filled with blood.

FIGURE 2.

Middle portion of the Placenta formed by the villi of the chorion. The figure represents a small portion of a villus magnified 350 times.

(*a*, *a*) Portions of vessels of the fœtal placenta.

(*b*, *b*) The glandular organ which completely surrounds all the villi, and in which are distinguished the external wall and the cells of the internal epithelial layer.

FIGURE 3.

Vertical section of the uterine surface of the Human Placenta (250 diameters).

(*a*, *a*) Layer of large cells of connective tissue which is in direct relation with the sub-mucous connective tissue of the uterus.

(*b*, *b*) A much thicker layer formed of round cells in the midst of loose connective tissue, known to anatomists by the name of decidua serotina.

(*c*, *c*) Internal surface of the said serotina transformed into fibrous tissue to limit the sanguineous sinuses of the placenta.

(*d*, *d*) The serotina changed into a glandular organ which enwraps all the villi of the chorion.

(*e*, *e*) Villi cut transversely, which show the vessels of the fœtal placenta within surrounded by the glandular organ.

(*f*) A large vascular trunk of the fœtal placenta surrounded by the glandular organ cut transversely at the base of the internal surface of the fœtal portion of the placenta.

(*g*) The same cut lengthwise. The vessels are wanting in the interior of this portion ; but the nuclei of the vessels (*e*, *e*) are seen in the interior of the ramifications of the villi which are in connection with the trunk aforesaid. The secretory cells seen in the interior are in continuity with those of the serotina.

(*h*) A utero-placental vein, half filled with blood, cut transversely. Its walls are formed by the fibrous metamorphosis of the cells of the serotina.

(*i*) A utero-placental artery, in the middle portion of the decidua serotina, also cut transversely.

EXPLANATION OF THE PLATES.

ILLUSTRATING THE UNITY OF THE ANATOMICAL TYPE OF THE PLACENTA.

PLATE I.

FIGURE 1.

Complete transverse section of a portion of the gravid uterus and placenta of a rabbit at the beginning of gestation.

(*a*) Uterine muscular tissue.

(*a'*) Uterine vessels.

(*b*, *b*) Lumina of the utero-placental vessels cut in different ways. From their totality results the formation of the placenta in its first phase of development.

(*c*, *c*) Cellular envelope of the aforesaid vessels constituting the cells of the decidua serotina and of the placenta.

(*d*, *d*) The old uterine mucous membrane tumefied, together with the underlying vasculo-cellular layer in course of destruction; all the parts indicated are detached from the inner surface of the uterine muscular tissue, and have been forced forward by the subjacent placental neoplasm.

FIGURE 2.

Complete transverse section of a portion of the placenta of the dog, about the middle of the period of gestation.

(*a*) Indication of the dilated and deformed utricular glands which form a trabecula with large interstices between the internal muscular surface of the uterus and the placenta.

(*b*, *b*) Net-work of injected maternal placental vessels showing that the cellular envelope that surrounds the vessels *b'*, *b'* extends from the uterine surface of the placenta to the chorion.

(*c*) The chorion with its large fœtal vessels cut across.

(*d*, *d*) The spaces that result from the reticulated arrangement of the aforesaid placental vessels. For the sake of greater clearness, the elements of the chorion are not shown in the figure; neither are the fœtal vessels which have their course in the spaces indicated. The relation between these parts is represented in the next figure.

FIGURE 3.

Represents the relations of the fœtal with the maternal portion of the placenta in the dog, magnified 500 diameters. The figure was taken from a horizontal section of a placenta at term of the animal, in which an injection had been made both in the fœtal and in the maternal part.

(*a*, *a*) Two portions of the maternal vasculo-cellular net indicated in the preceding figure by *b'*, *b'*.

(*b*, *b*) Lumina of the internal or maternal vessel.

(*c*, *c*) External cellular envelope of the aforesaid vessel.

(*d*) The same parts with a transverse cut. The inner maternal vessel and the outer cellular layer are indicated by the same letters *b* and *c*.

(*e*, *e*) Fœtal vessels and chorial elements interposed in the maternal vascular net-work corresponding to the spaces left empty, and shown at *d* in the preceding figure.

(*f*, *f*) Cellular elements of the chorion in the midst of which the fœtal vessels circulate.

(*g*, *g*) Minute and crowded capillary net formed by the fœtal vessels, which is distributed in the cellular envelope that clothes the maternal vessels of the placenta.

PLATE II.

FIGURE 1.

Represents the entire transverse section of a uterine horn of *Mus decumanus* in the segment where the ovum was arrested at the beginning of gestation.

(*A*) Corresponds to the convex and free inferior curvature of the horn of the uterus.

(*B*) Corresponds to the superior curvature to which is attached the suspensory ligament of the uterus.

(*a*) Suspensory ligament of the uterus.

(*b*, *b*) Outer wall and muscular tissue of the uterus.

(*c*) The ovum.

(*d*) Cavity of triangular shape still partly covered with the old epithelium of the mucous membrane of the non-gravid uterus, representing, in the segment of the gravid uterine horn, the old cavity of the non-gravid uterus.

(*e*) Narrow crevice reaching from the ovum (*c*) to the above-named triangular cavity. At the inner edges of this crevice every trace of the epithelium of the old uterine mucous membrane is lost.

(*f*, *f*) Cellulo-vascular neoplasm that embraces the ovum at the place where it is arrested. This holds the place of all the anatomical elements that constituted the mucous membrane of the non-gravid uterus, including the thick vasculo-glandular layer as far as the inner muscular tissue of the uterus.

(*g*, *g*) Traces of old utricular glands undergoing complete destruction.

(*h*) Place where the before-mentioned neoplasm will be, invariably in the rat, replaced by the placenta.

(*i*) Place where the before-mentioned neoplasm will be, invariably in the rat, replaced by the decidua reflexa.

(*l*, *l*) Place where the before-mentioned neoplasm will be, invariably in the rat, replaced by the decidua vera.

FIGURE 2.

Represents a longitudinal section of a portion of uterine horn of the same *Mus decumanus*, comprehending the segment in which the ovum was arrested, and the neighboring portions of the uterine horn which remained empty. It brings out the thorough transformation that has taken place in the uterine mucous membrane and the subjacent parts in the place where the ovum was arrested.

(*a*, *a*) External wall and muscular tissue in the segment of the uterine horn where the ovum was arrested.

(*b*, *b*) External wall and muscular tissue in the portions of the uterine horn that remained empty.

(*c*) The cellulo-vascular neoplasm that embraces the ovum indicated by *f* in the preceding figure.

(*d*, *d*) Remains of the old utricular glands.

(*e*) The ovum.

(*f*,*f*) Uterine cavity in the portions of the horn that remained empty.

(*g*, *g*) Uterine mucous membrane in the same, and tumefied subjacent connective layer. The utricular glands are enlarged, but there is not observed in these portions of the mucous membrane any change in the different histological elements composing it.

PLATE III.

FIGURE 1.

Represents half of an entire transverse section of the uterus and placenta of a *Mus musculus*. The placenta has not yet reached its complete development.

(*a*, *a*) Muscular wall of the uterus.

(*b*, *b*) Surface of the internal muscular tissue which is covered with a new epithelium that represents by itself all the future elements of the mucous membrane of the non-gravid uterus, including the glandulo-vascular layer that will be underneath it.

(*c*) Decidua reflexa formed by two layers of different elements.

(*d*) The external layer of the same, composed of cellular elements identical with those of the glandular portion of the placenta (*i*).

(*e*) The internal layer, composed of a cellulo-vascular trabecula.

(*f*) Cellulo-vascular trabecula of the decidua vera.

(*g*) Portion of the decidua vera in which every trace of the above cellulo-vascular trabecula is lost.

(*h*, *h*) Decidua serotina.

(*i*) Glandular or uterine portion of the placenta not reached by the villi of the chorion.

(*l*) Vascular or upper portion of the placenta.

(*m*) Central portion of the placenta adherent with the chorion. The fœtal vessels enter it to be distributed in the vascular portion of the placenta.

(*n*, *n*) Free chorion. There has not yet taken place the union of the chorion with the decidua reflexa to form that species of pocket which is observed in the rat on the fœtal surface of the placenta when it has completed its phases of development.

(*o*, *o*) Pavement epithelium which covers the inner surface of the decidua and the fœtal surface of the placenta.

PLATE IV.

FIGURE 1.

Represents half of a complete transverse section of the fully developed uterus and placenta of the *Cavia cobaya*.

(*a*, *a*) Muscular walls of the uterus.

(*b*) Internal surface of the uterus, covered with a new epithelial layer, representing all the elements of the old mucous membrane of the non-gravid uterus, including the glandulo-vascular layer beneath, which perished after conception by the formation of the decidua.

(*c*) Decidua vera, clothed with a special epithelium on the surface towards the uterus (*c'*), as well as on that towards the fœtus (*c''*).

(*d*) Portion of the decidua reflexa in connection with the uterine muscular tissue. Noticeable in this portion are the utero-placental vessels of new formation everywhere surrounded by a layer of placental cells.

(*e*) The same, surrounding the peduncle of the placenta. There are noticed in this portion the large placental vessels that are in relation with the utero-placental ones here shown at the base of the reflexa, and with the irregularly ectasic capillaries that course in the peduncle of the placenta.

(*f*,*f*) The same, which invests in great part the body of the placenta. Its cellular elements are about to blend with those of the chorion.

(*g*) Place where the aforesaid fusion occurs.

(*h*) Epithelium that covers the external surface of the decidua reflexa in the place where it invests the peduncle of the placenta.

(*i*, *i*) Thick epithelial layer, proliferating at different points in the form of epithelial buds, which clothes the placental reflexa. This epithelium is in continuation with that which also clothes the fœtal surface of the decidua vera (*c''*).

(*l*) Portion of the chorion that adheres to the placenta.

(*m*) Free chorion.

(*n*) Peduncle of the placenta. In this portion of the placenta are to be noticed: first, the net-work of the irregularly ectasic placental capillary vessels; second, the varying volume of the neo-formed cellular elements (*n'*), some of which are gigantic.

(*o*) Central or cotyledonal portion of the placenta. (See Fig. 3 of this Plate.)

(*p*) Peripheral or vascular portion of the placenta, in which the fœtal vessels come in contact with the cellular layers that invest the vessels of the maternal portion of the placenta. (See Fig. 2 of this Plate.)

(*q*) Central cavity of the placenta, filled with a mass of chorial tissue, in which circulate the fœtal vessels which are carried to the cotyledonal portion of the placenta.

FIGURE 2.

Represents a portion of the vascular part of the placenta of the *Cavia cobaya* highly magnified (500 diameters). (See *p* of the preceding figure.)

(*a*) Placental vessels injected, which, together with the cellular envelope surrounding them, constitute in this part the maternal portion of the placenta.

(*b*) The above-named cellular envelope of the placental vessels, with which the vessels that constitute the fœtal portion of the placenta come in contact.

(*c*) The lumina of these fœtal vessels.

(*d*) Large fœtal vessel surrounded with cellular elements of the chorion.

(*e*) The aforesaid elements which are found in contact with the cells that surround the placental vessels.

FIGURE 3.

Represents a portion of the cotyledonal part of the placenta of the *Cavia cobaya* highly magnified (500 diameters). (See *o* of Fig. 1.)

(*a, a*) Vessels in the net-work of the irregularly ectasic capillaries of the pedunclе of the placenta.

(*b, b*) Irregularly thick and festooned layer which covers all the bottom of the central or cotyledonal part of the placenta in the cavia.

(*c, c*) Cellular elements of the chorion.

(*d, d*) Fœtal vessels which draw the nutriment for the fœtus from this portion of the placenta.

FIGURE 4.

Represents a portion of a fœtal villus of the human placenta magnified 500 diameters.

(*a, a*) Larger vascular loop of the trunk of the villus in direct relation with the vascular loc 'he branches.

(*b*, *b*) Chorial tissue that surrounds the above vessels, in the midst of which appear granulous and oval nuclei.

(*c*, *c*) Cellular covering furnished to the villi by the external wall of the maternal vessels, known to anatomists as the deep-seated epithelial layer of the villi. At *c'* the covering is represented as completed.

(*d*) The modified endothelial wall of the maternal vessels, called by anatomists the superficial epithelial layer of the villi. This wall is most evident in the place where it covers the epithelial buds (*d'*).

(*e*) Indicates the formative process of a branch of a villus by protrusion of a vascular loop against the walls of the maternal vessel.

(*f*) A complete branch of a villus.

(*g*) One of the many forms presented by the so-called epithelial buds, observed so frequently on the trunks and branches of the villi.

(*h*) Another of these buds, of pedunculate form, which, perhaps, may represent the arrest of development in the formative process of a villus, as the foregoing represents a phase of progressive development.

PLATE V.

Represents the plans of the different forms of placenta hitherto observed, showing the unity of anatomical structure in that organ in the mammalia and in the human species.

In the upper division (*A*) are represented the plans of the diffused and multiple placentæ, in which the glandular form of the maternal portion is clearly evident.

In the lower division (*B*) are represented the plans of the single placentæ, whether of zonarial or discoidal form. In these the glandular form of the maternal portion is concealed by the intimate union of the absorbent fœtal portion with the secretory maternal portion.

In both compartments the black parts belong to the mother, and the light to the fœtus.

The letters common to the plans indicate the same parts for all.

COMPARTMENT A.

NUMBERS 1, 2.

Diagram representing the typical and fundamental anatomical form of the two parts constituting the placenta in all the mammalia and in the human species. Both are alike formed by a simple villus, the

function alone being different, absorbent in the fœtal portion (No. 7), secretory in the maternal portion (No. 2).

(*a*) Walls of the gravid uterus.

(*b*) Uterine surface of the placenta.

(*c*) Uterine vessels.

(*d*) Vascular loop of the maternal villus representing the placental vessels.

(*e*) Secretory epithelium which covers the loop representing the placental cells.

(*f*) Chorion.

(*g*) Fœtal vessels in the chorion.

(*h*) Vascular loop of the fœtal villus representing the villi of the chorion. The absorbent fœtal villus is still covered with a proper epithelium.

NUMBERS 3, 4.

Diagram representing the fœtal and maternal portions of the simplest forms of diffused placenta, observed in the cetacea and in the sow. The letters indicate the same parts as in the preceding scheme. The fundamental typical form is very clearly preserved in both parts of the placenta. The repetition *in loco* and the crowding together of many maternal villi occasion the formation of small crypts into which enter the fœtal villi.

NUMBERS 5, 6.

Diagram representing the fœtal and maternal portions of the placenta of the solipeds. The letters indicate the same parts as in the foregoing. The maternal crypts are more perfect than in the preceding scheme, and appear in the form of simple glandular follicles, into which enter the fœtal villi.

NUMBERS 7, 8.

Diagram representing the fœtal and maternal portions of the multiple placenta of a ruminant. The letters indicate the same parts as before. The glandular follicles resulting from the union and aggregation of many maternal villi give the maternal portion of the placenta the appearance of a compound gland; the typical form of the primitive villus, fœtal as well as maternal, is not lost, but remains as in the preceding diagram by this complication of form, which is more apparent

COMPARTMENT B.

NUMBERS 9, 10.

Diagram representing the vascular portion of the placenta of the cavia, with which may be compared the figures drawn from nature in Plate IV., Fig. 2. The letters indicate the same parts as in the preceding. The typical form of the two villi is preserved, except that by the intimate union of the two parts of the placenta the fœtal villus loses the proper epithelium, as in all cases of single placenta. The walls of the vessel of the absorbent fœtal villus thus come into direct contact with the secretory epithelium of the maternal villus.

NUMBERS 11, 12.

Diagram representing the placenta of a carnivorous animal, — that of the dog, — drawn from nature in Plate I., Figs. 2 and 3, with which this may be compared. The letters indicate the same parts as before. Comparing this scheme with the previous one there appears this peculiarity only: the vessels of the fœtal villi do not run parallel to the vessels of the maternal villus, but form, instead, a net-work of minute capillaries all about the epithelium, or the placental cells that invest the vessel of the maternal villus.

NUMBERS 13, 14.

Imaginary diagram copied from the previous and accurate one of the dog, to show what deceptive appearances are produced by the mere ectasia of the vascular loop of the maternal villus. The letters indicate the same parts as before. On the left is represented incipient ectasia in the vascular loop aforesaid (*d*). On the right is shown the ectasic process as complete. This is the sole origin of three illusions: first, that instead of the ectasic maternal vessel a lacuna is formed; second, that the fœtal villi swim in the maternal blood; third, that the epithelium of the maternal vessel that comes in contact with the villus belongs to the fœtus and not to the mother. These are the three deceptive appearances which have prevented anatomists from ascertaining the structure of the human placenta, as better appears in the following diagram.

NUMBERS 15, 16.

Diagram of the human placenta. There are represented two cotyledons, the one (*C*) in course of development, the other (*D*) as fully developed. The letters *a*, *b*, *c*, *d*, *e*, *f*, *g*, *h* correspond to the same parts indicated in all the preceding. By the dilatation of the vessel of the maternal villus (*C*) the fœtal villi (*h*) which proliferate push forward and bend in the walls of the vessel into its cavity (*o*). When the development is complete (*D*) the cells of the apex of the maternal villus (*i*) are borne against the chorion (layer of the sub-chorial decidua). These sides of two maternal villi come in contact with each other (*l*), and form one of the so-called septa of the cotyledons. At *m* is indicated one of the so-called roots of attachment of Kölliker in a villus. The three illusions shown in the preceding imaginary scheme are exactly met with in this actual plan of a cotyledon of the human placenta.

Pla.I.

J.B.Ercolani Structure glandulaire du Placenta

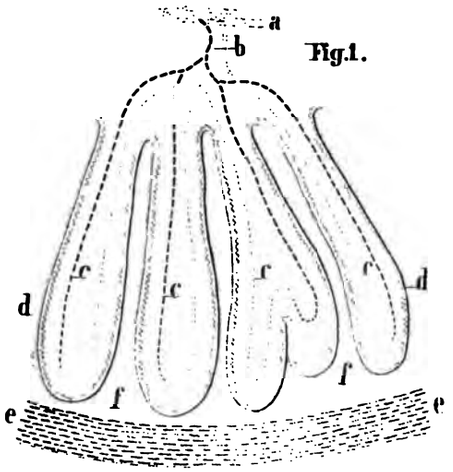

Fig.1.

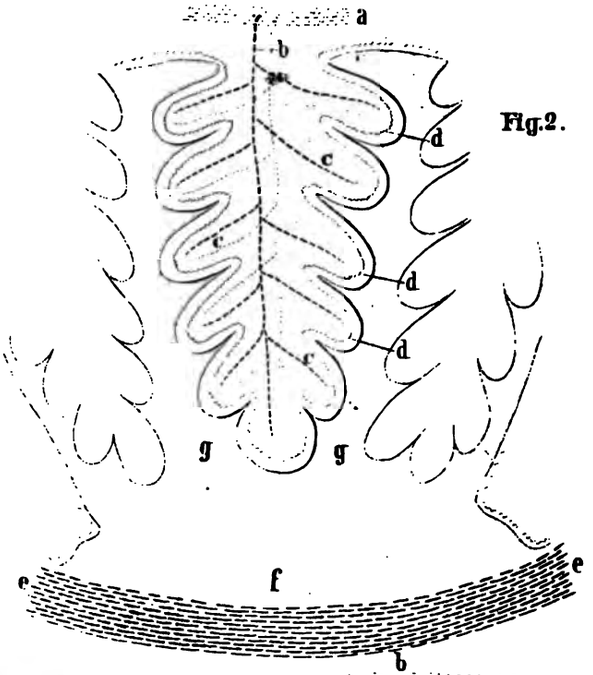

Fig.2.

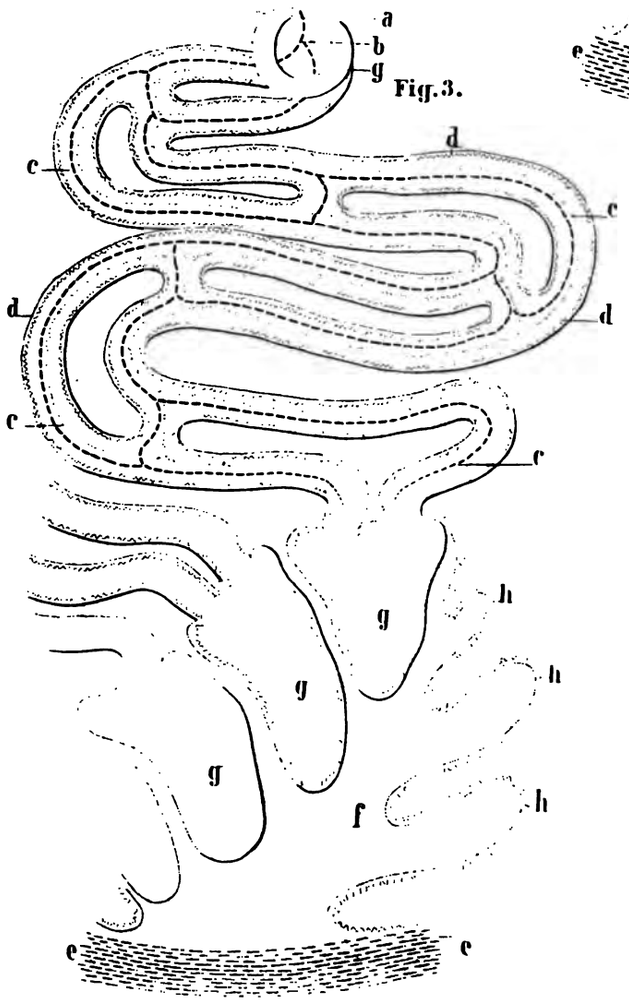

Fig.3.

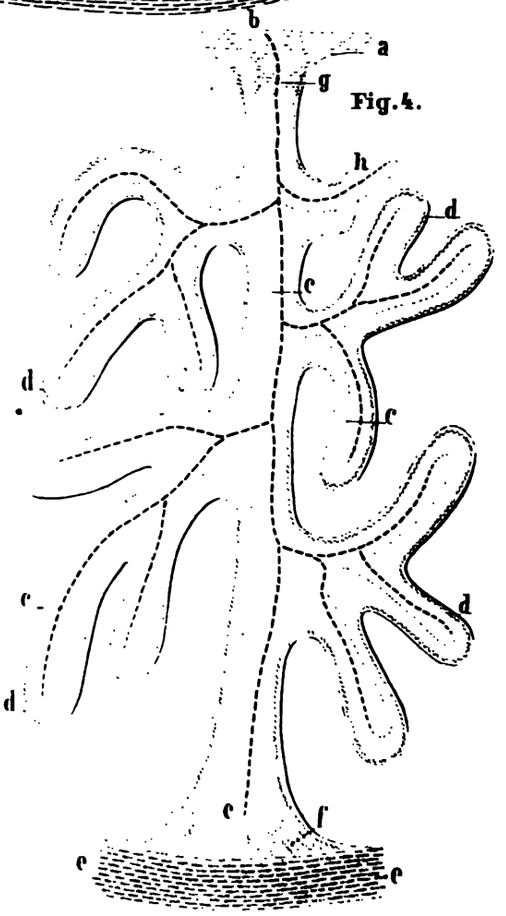

Fig.4.

Corto i ad nat. delin.

C. Bettini sculpit.

Litheg. Thumb

Fig. 1.

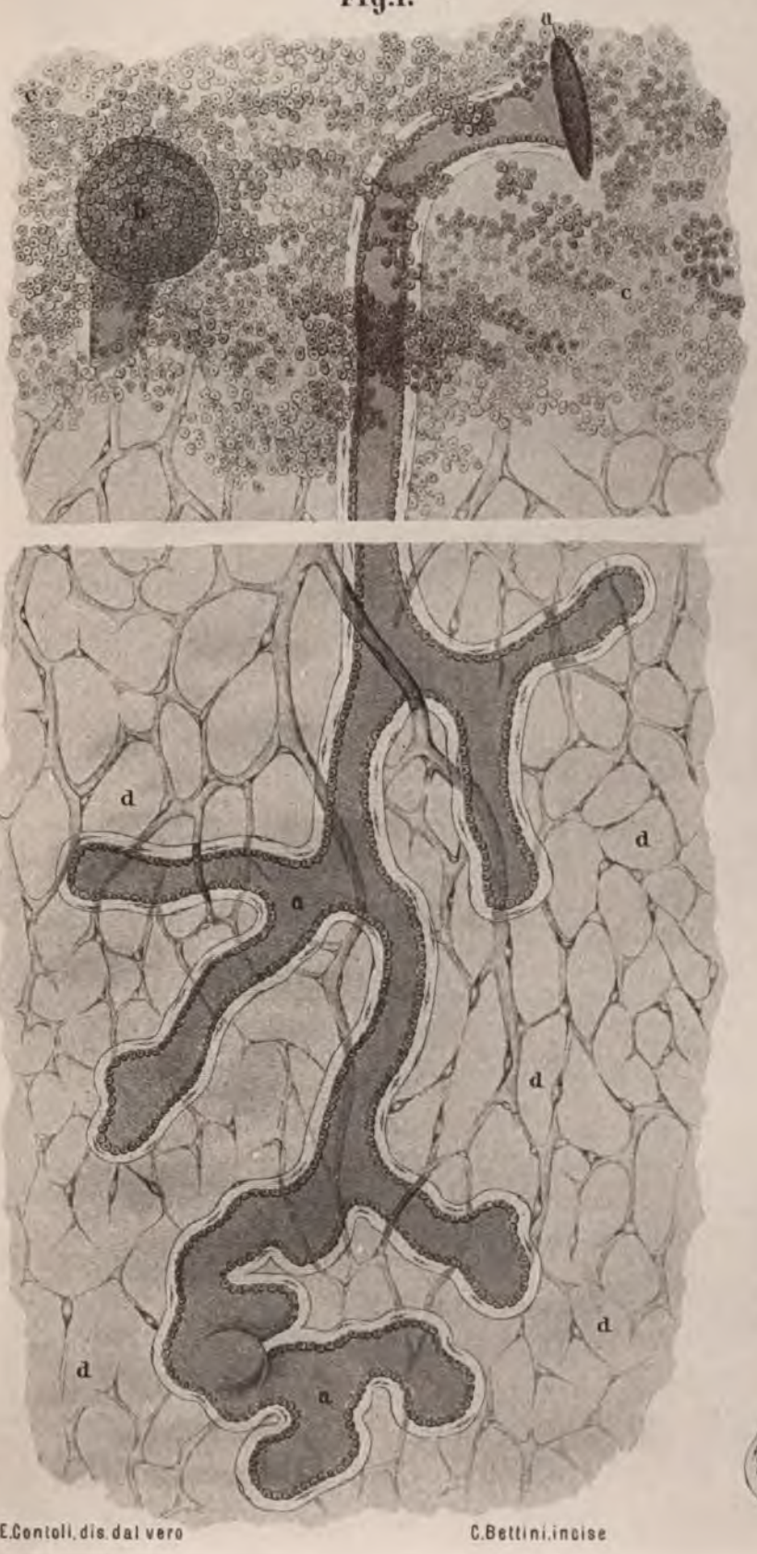

Fig. 2.

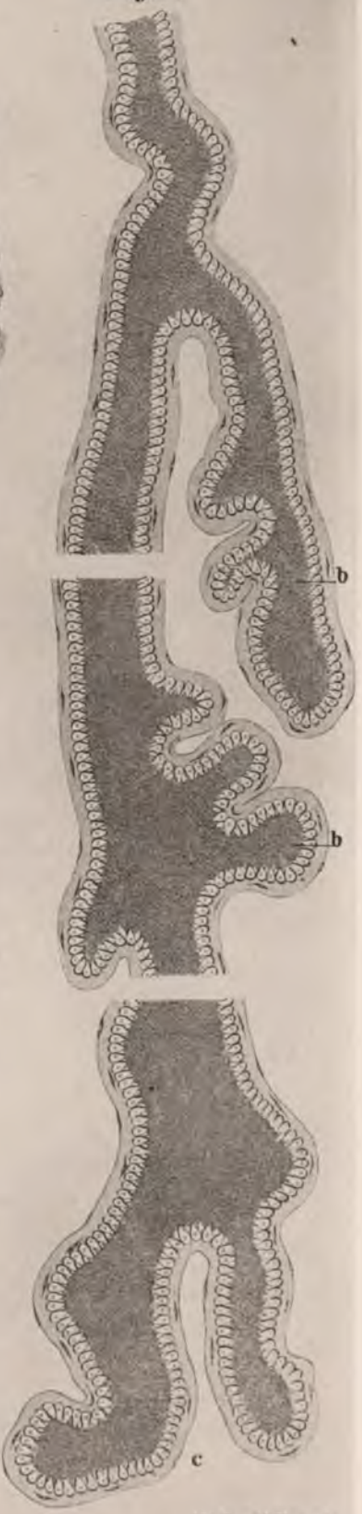

E. Contoli, dis. dal vero C. Bettini, incise Lit. Guglª Thumb

Fig. 2.

Fig. I.

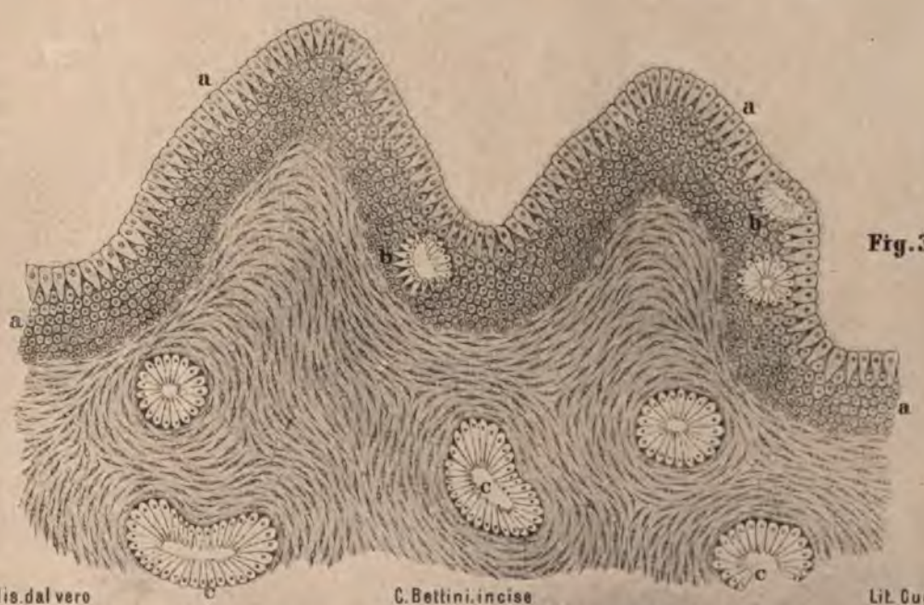

Fig. 3.

E. Contoli, dis. dal vero C. Bettini, incise Lit. Cugl.º Thumb

Fig. 1.

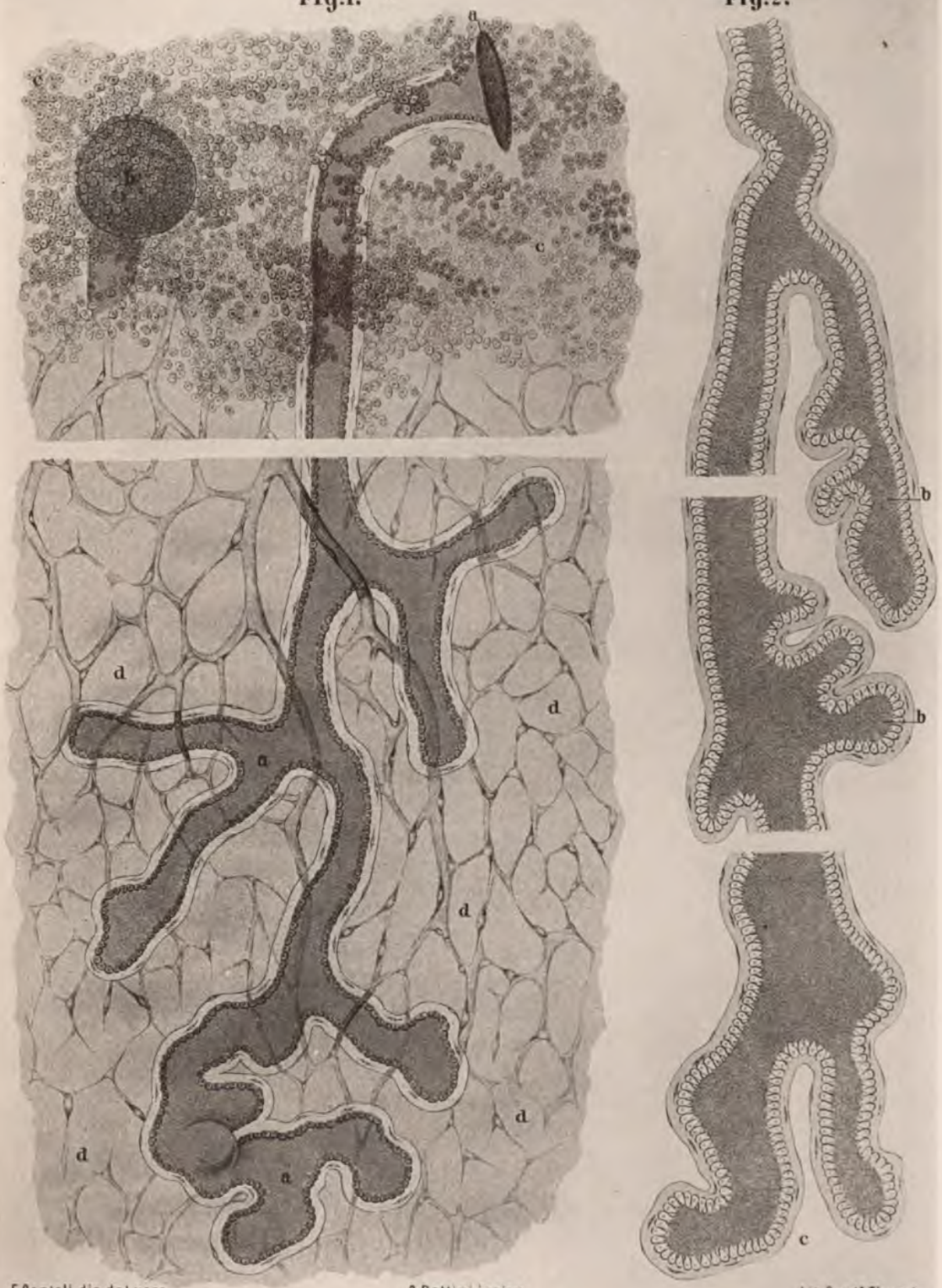

Fig. 2.

E. Contoli. dis. dal vero C. Bettini. incise Lit. Gugl° Thumb

Fig. 2.

Fig. I.

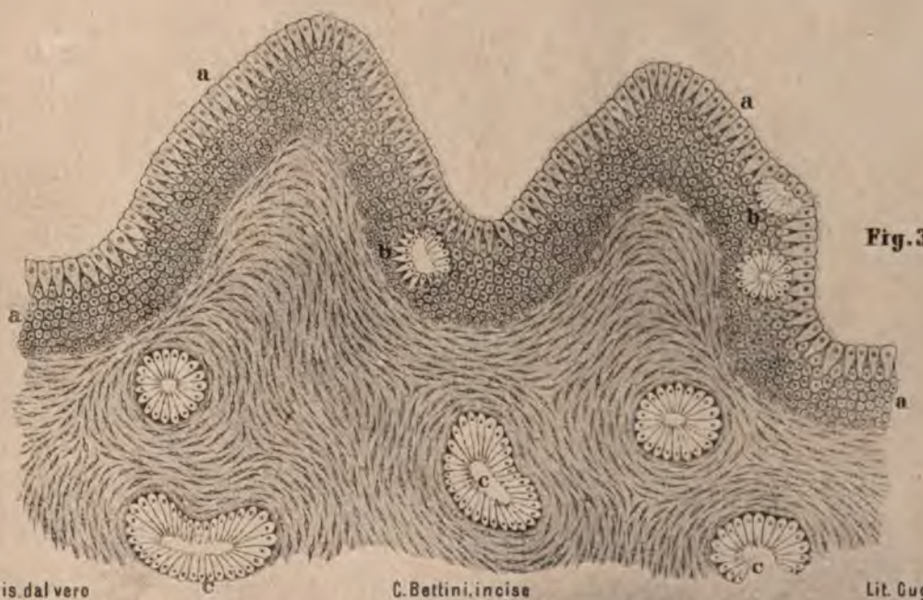

Fig. 3.

E. Contoli, dis. dal vero C. Bettini, incise Lit. Guglº Thumb

Pla. I.

J.B.Ercolani Structure glandulaire du Placenta

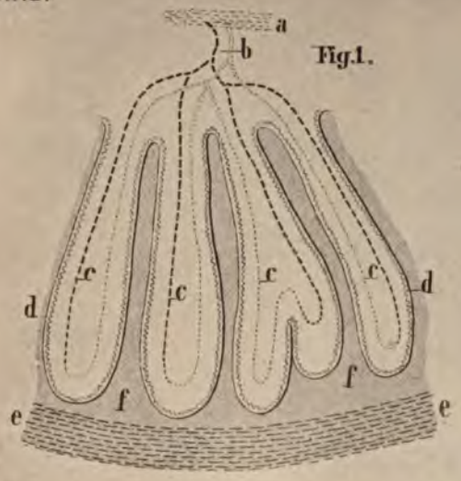

Fig.1.

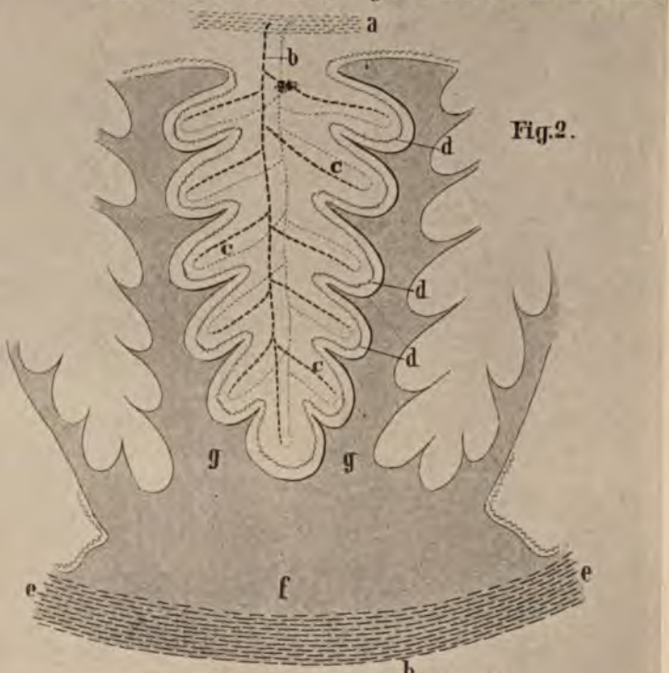

Fig.2.

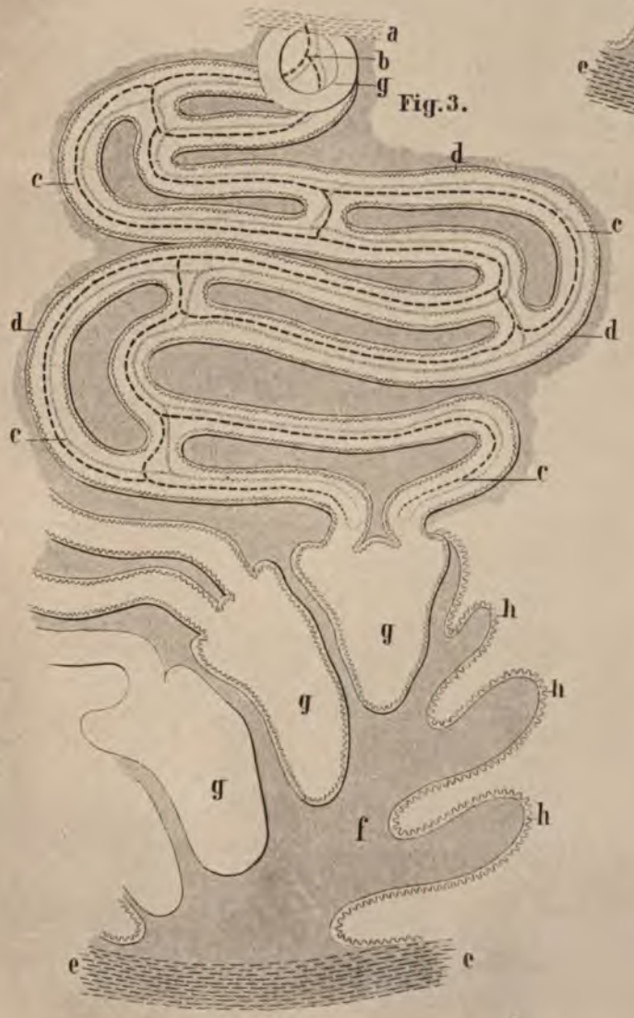

Fig.3.

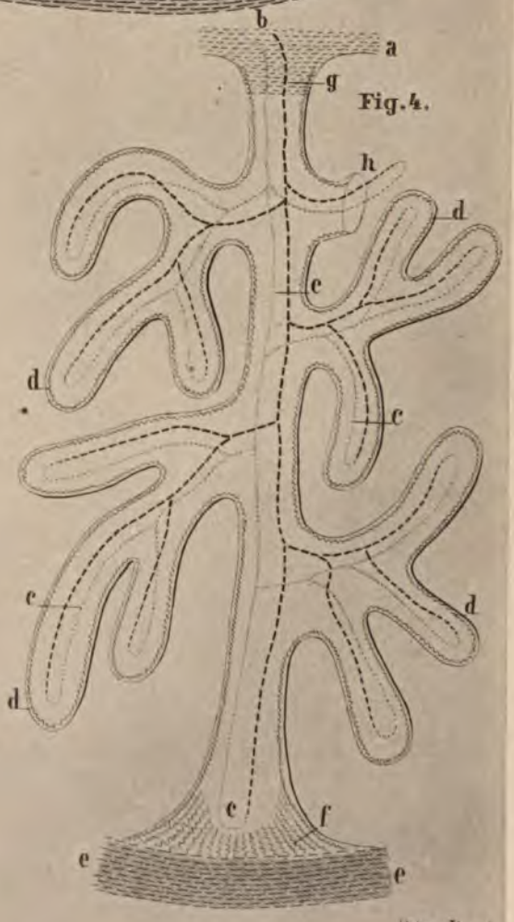

Fig.4.

Contoli ad nat: delin:

C Bettini sculpit:

Lithog. Thumb.

Fig. 1.

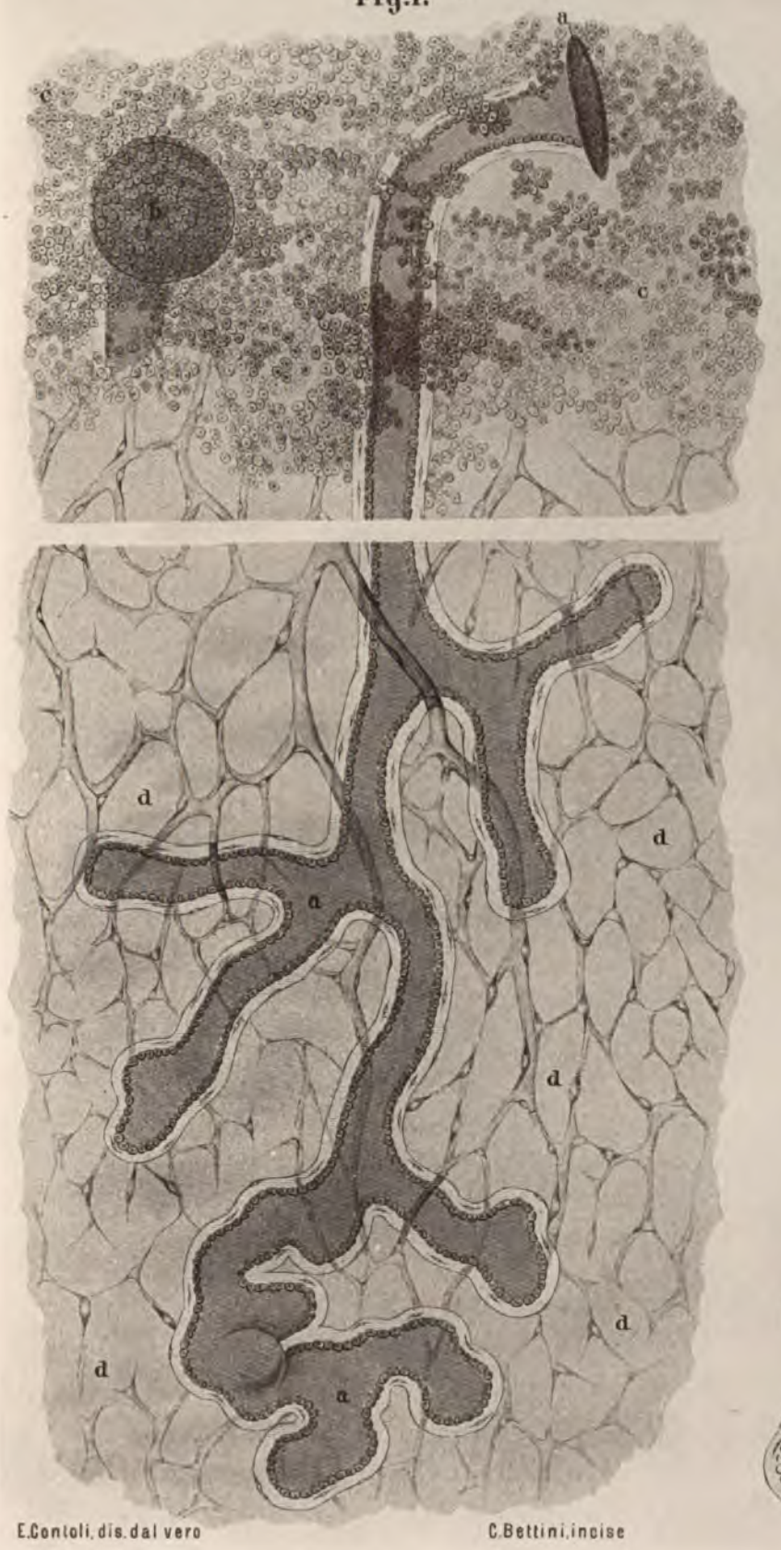

Fig. 2.

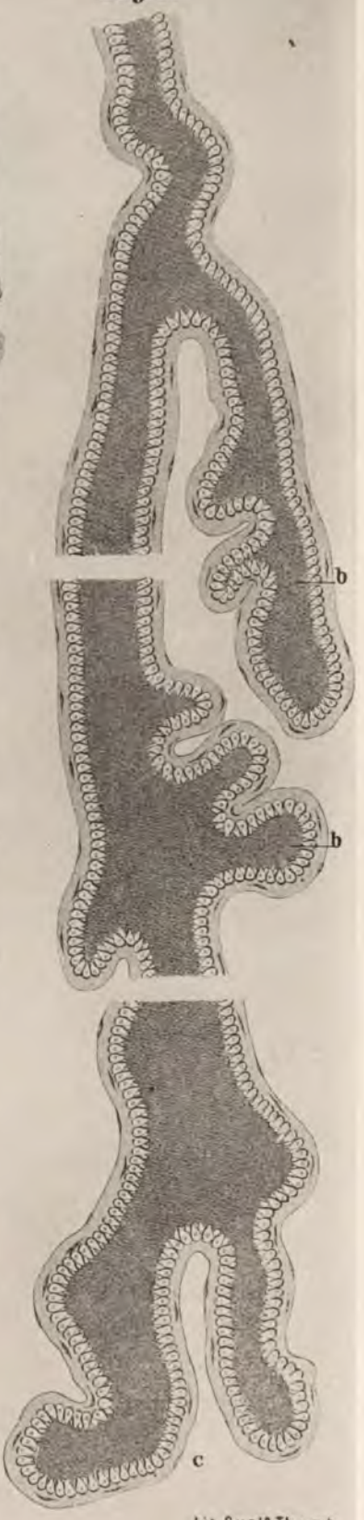

E. Contoli, dis. dal vero C. Bettini, incise Lit. Gugl.º Thumb

Fig. 2.

Fig. 1.

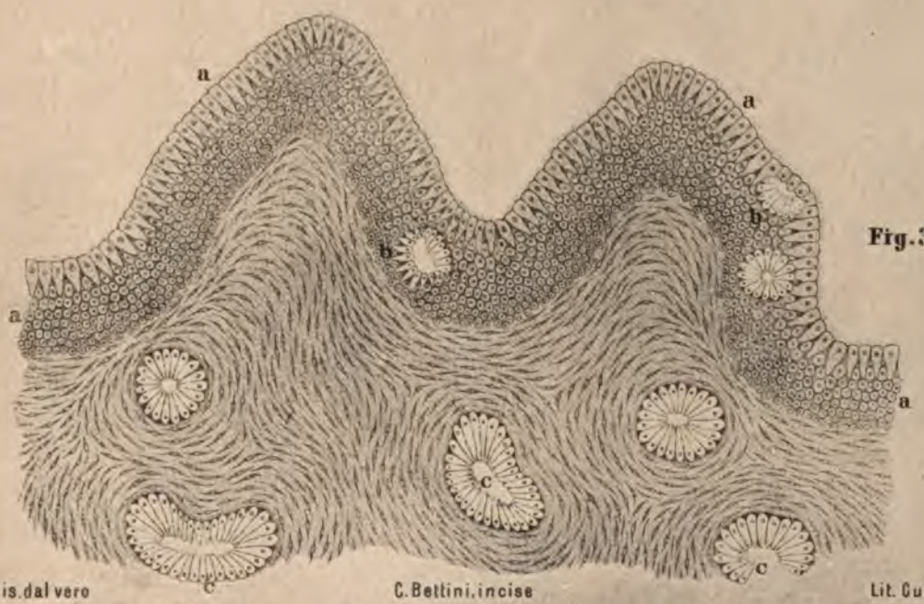

Fig. 3.

E. Contoli, dis. dal vero C. Bettini, incise Lit. Gugl° Thumb

Fig. 1.

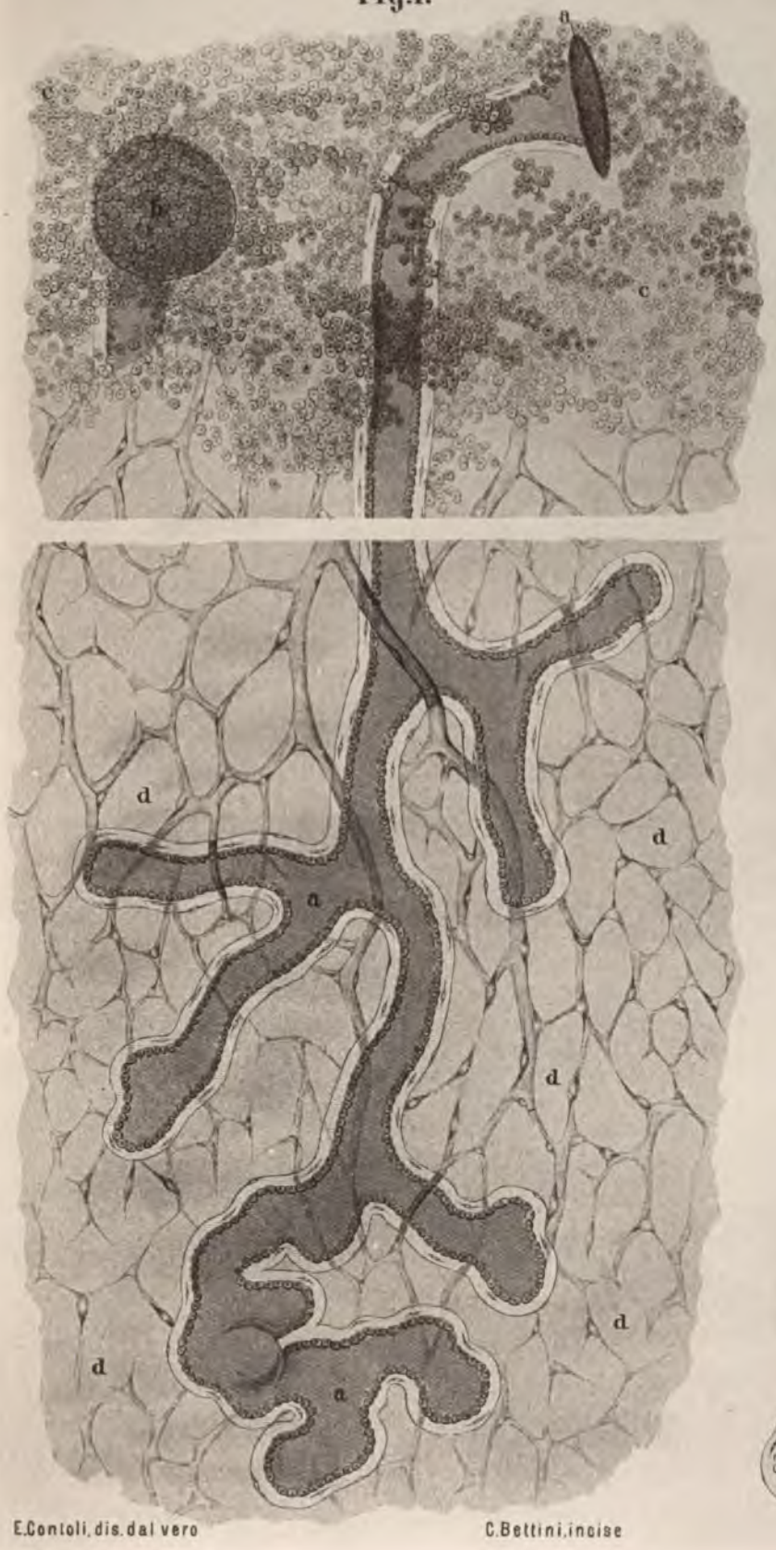

Fig. 2.

E. Contoli, dis. dal vero C. Bettini, incise Lit. Gugl.º Thumb

Fig. 3.

Fig. 1.

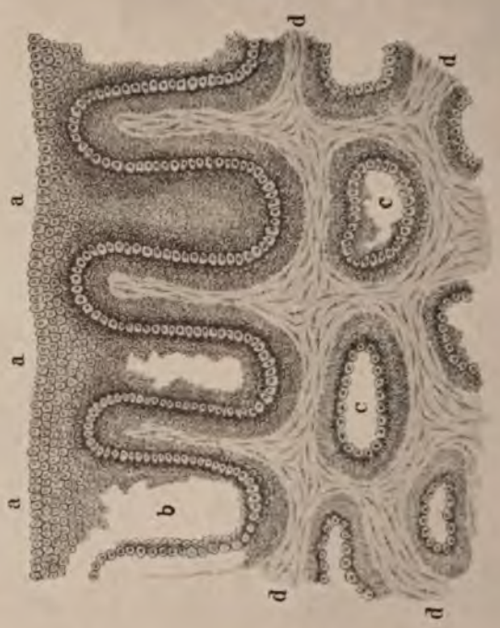

Fig. 4.

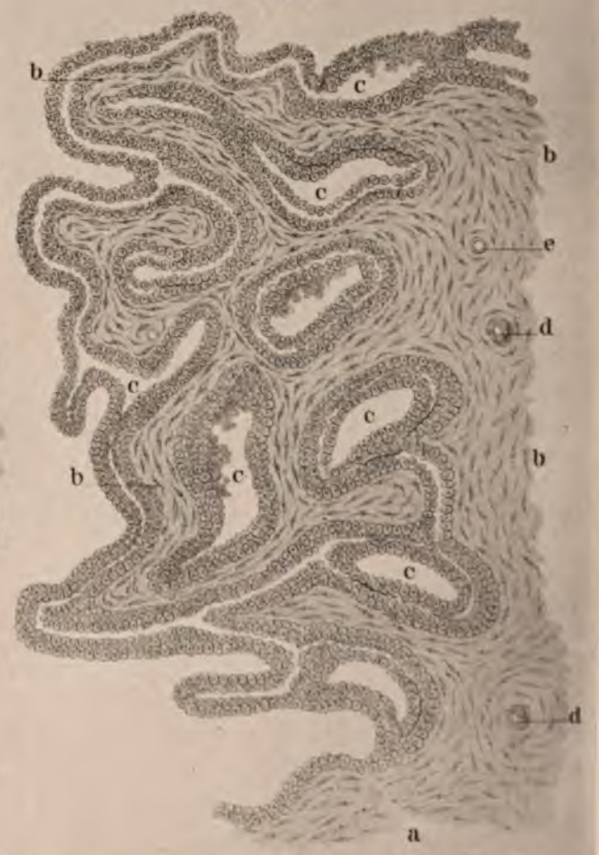

Fig. 2.

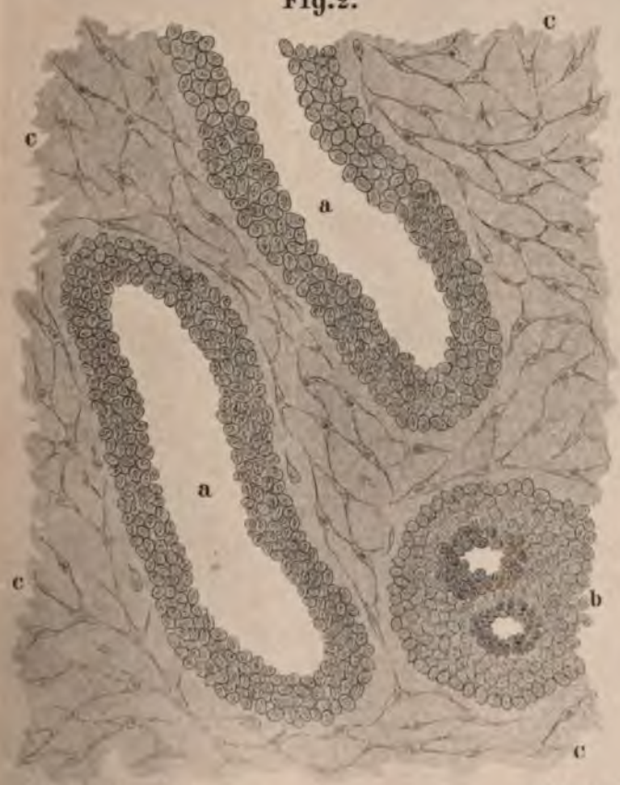

E. Contoli. dis. dal vero

C. Bettini. incise

Lit. Gugl.ª Thumb.

Fig. 1.

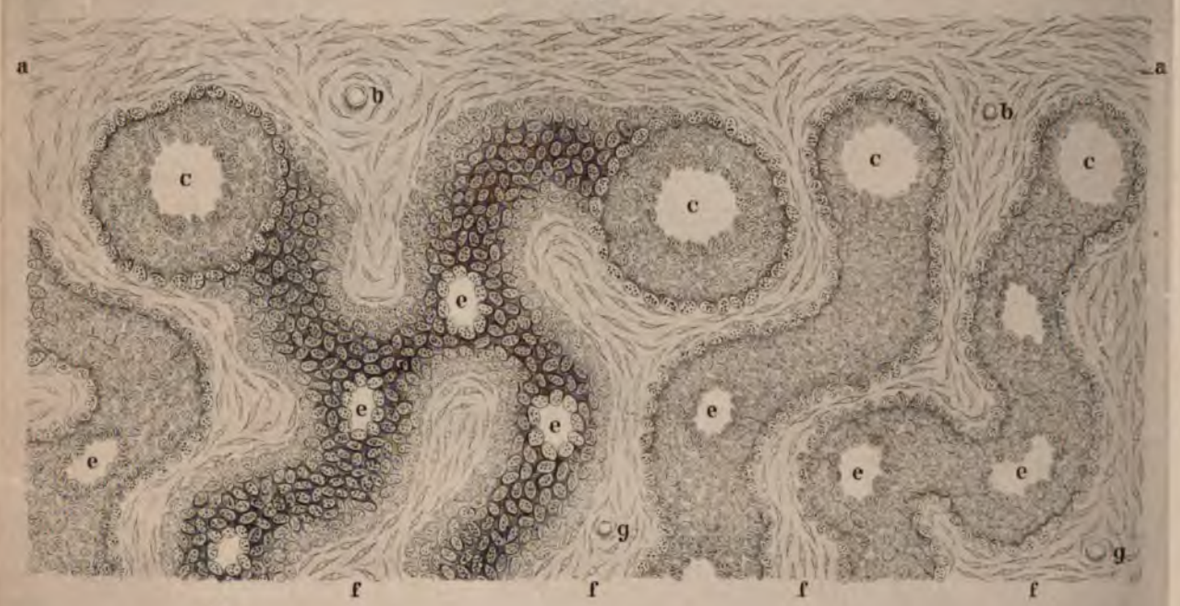

Fig. 2.

F. Contoli dis. dal vero — C. Bettini incise — Lit. Gugl.e Thumb

Fig. 1.

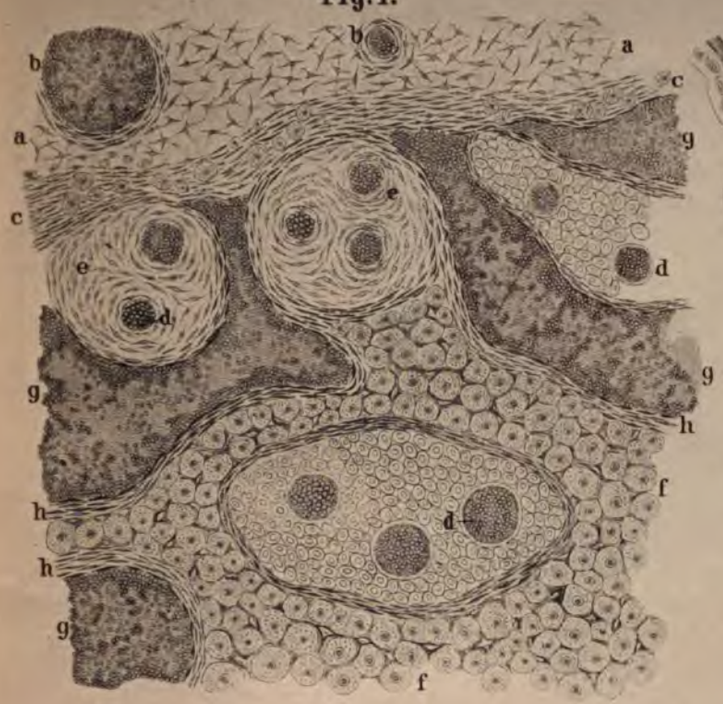

Fig. 2.

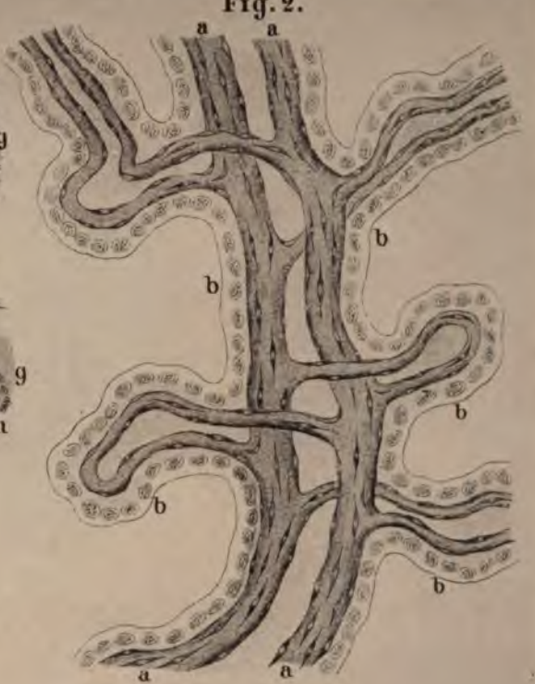

Fig. 3.

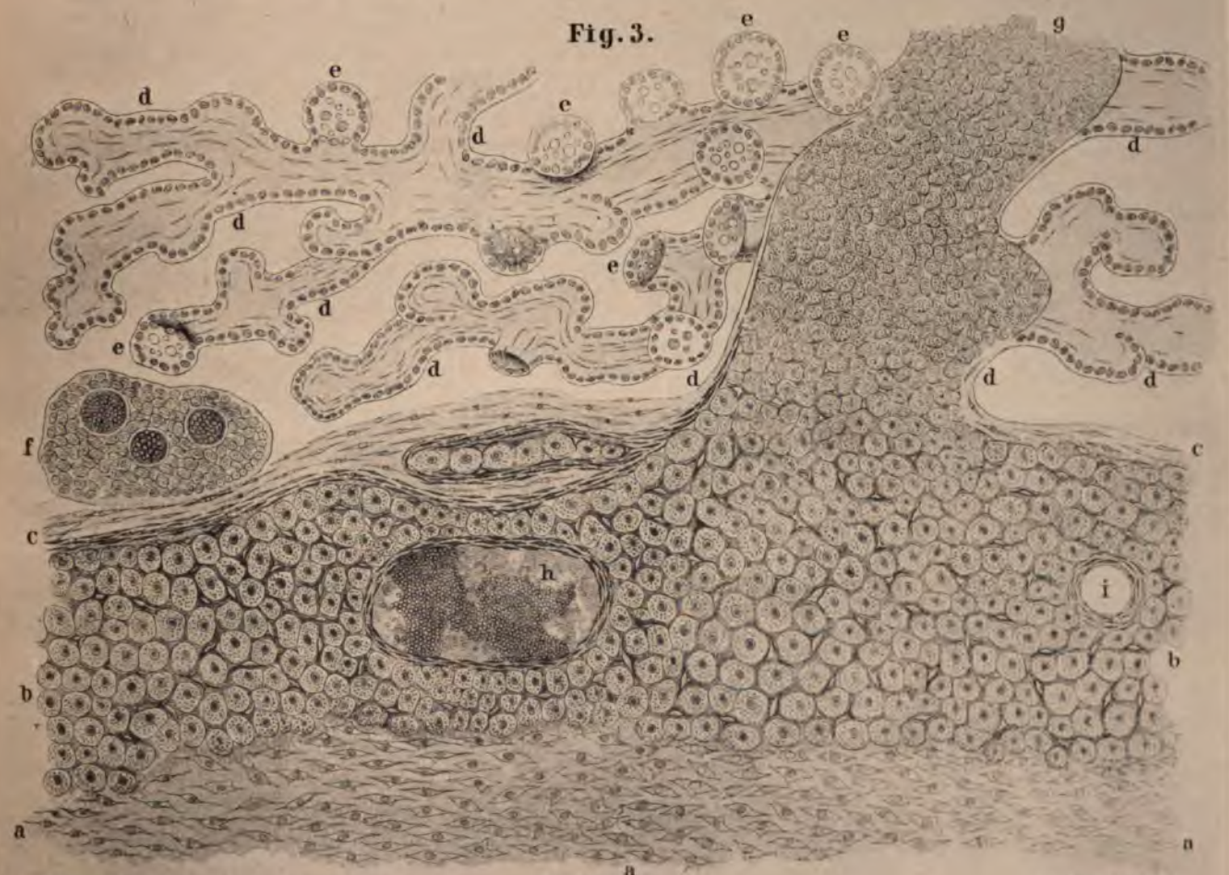

E. Contoli. dis. dal vero — C. Bettini. incise — Lit. Gugl.ª Thumb.

F. 1.

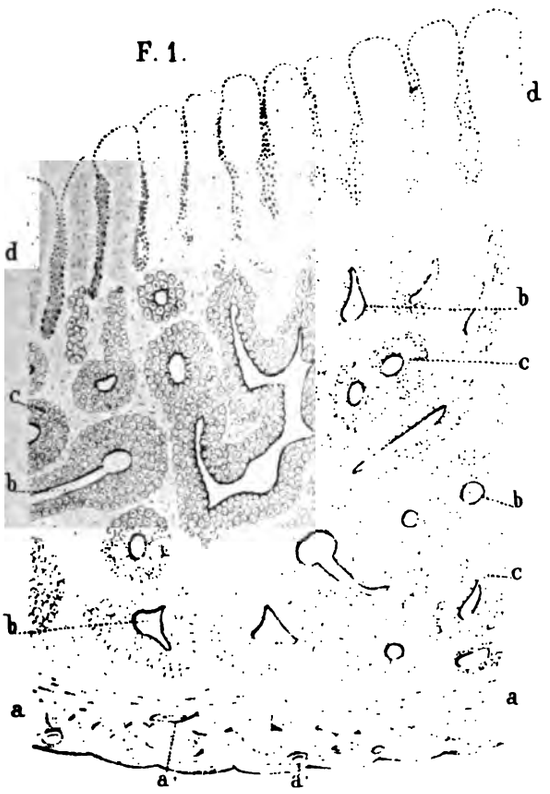

F. 2.



F. 3.

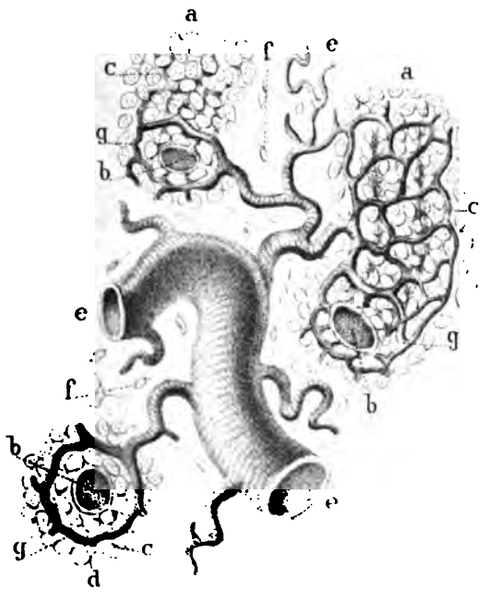

G. Piana dis.° dal vero Bettini dis.° in pietra Lit. G. Wenk.

G.B.Ercolani Tav. III.

F. 1.

O. Piana dis.t dal vero.

Bettini dis.t in pietra

Lit. G Wenk.

F. 1.

G. Piana dis.° dal vero

Bettini dis.° in pietra

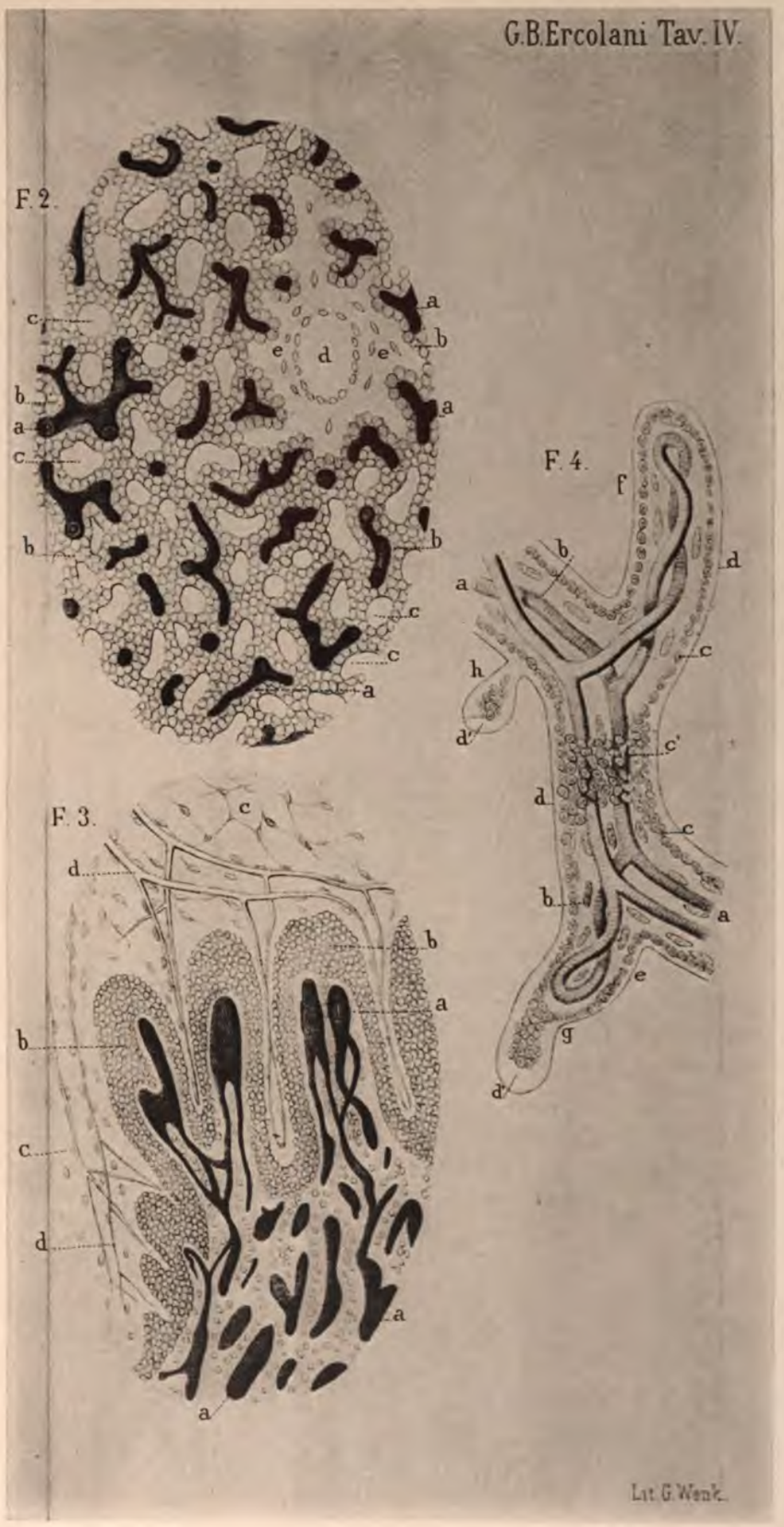
G.B.Ercolani Tav. IV.
F. 2.
F. 3.
F. 4.
Lit. G. Wenk.

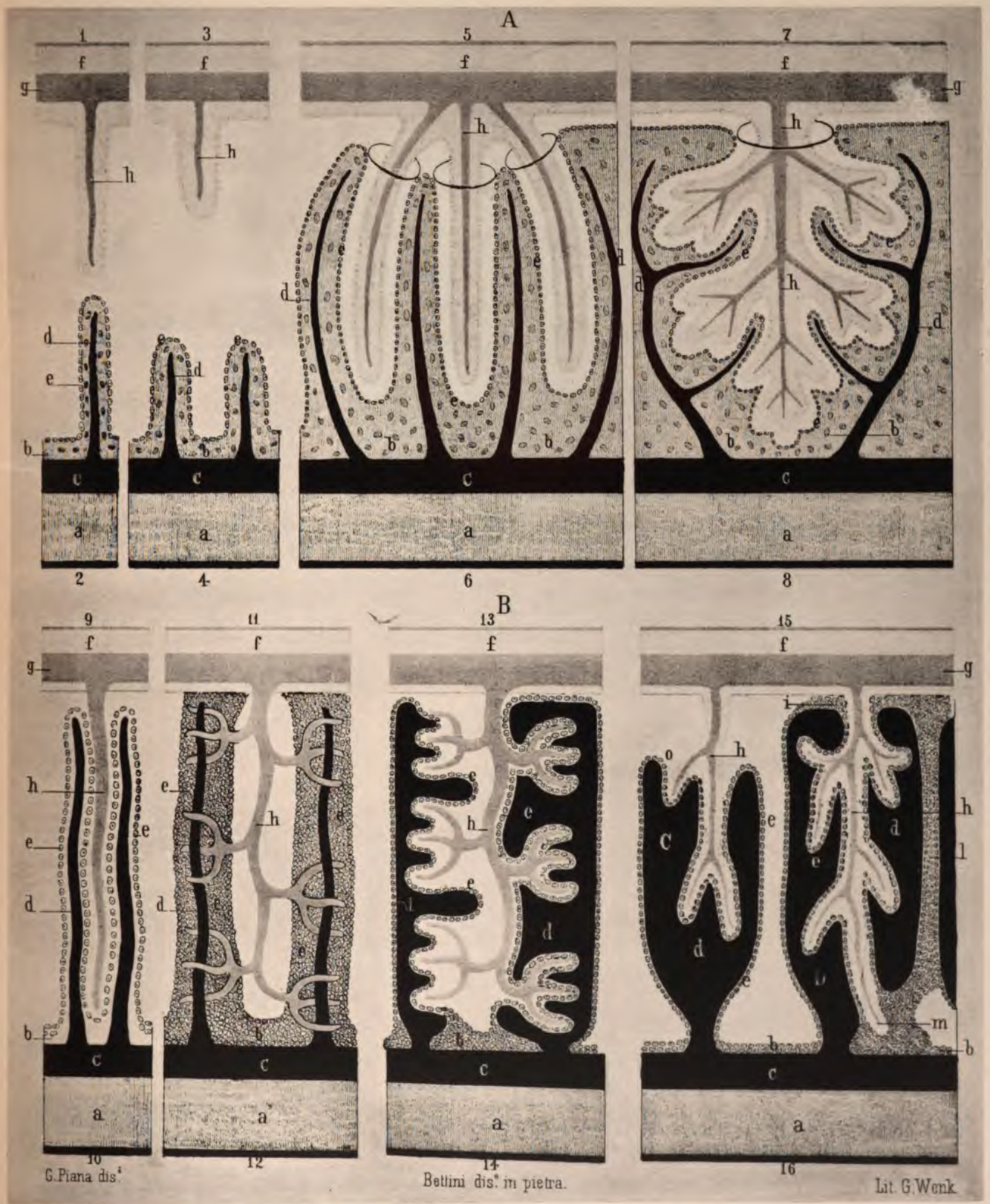
A
1
3
5
7
f
g
h
d
e
b
c
a
2
4
6
8
B
9
11
13
15
i
o
m
l
10
12
14
16
G.Piana dis.t
Bettini dis.t in pietra.
Lit. G.Wenk

F. 1.

m
l
g
f
p
c
c'
i
c
i'
f'
b
e
h
e
a
d
a
q
o
n
n'
G Piana dis.° dal vero
Bettini dis.° in pietra

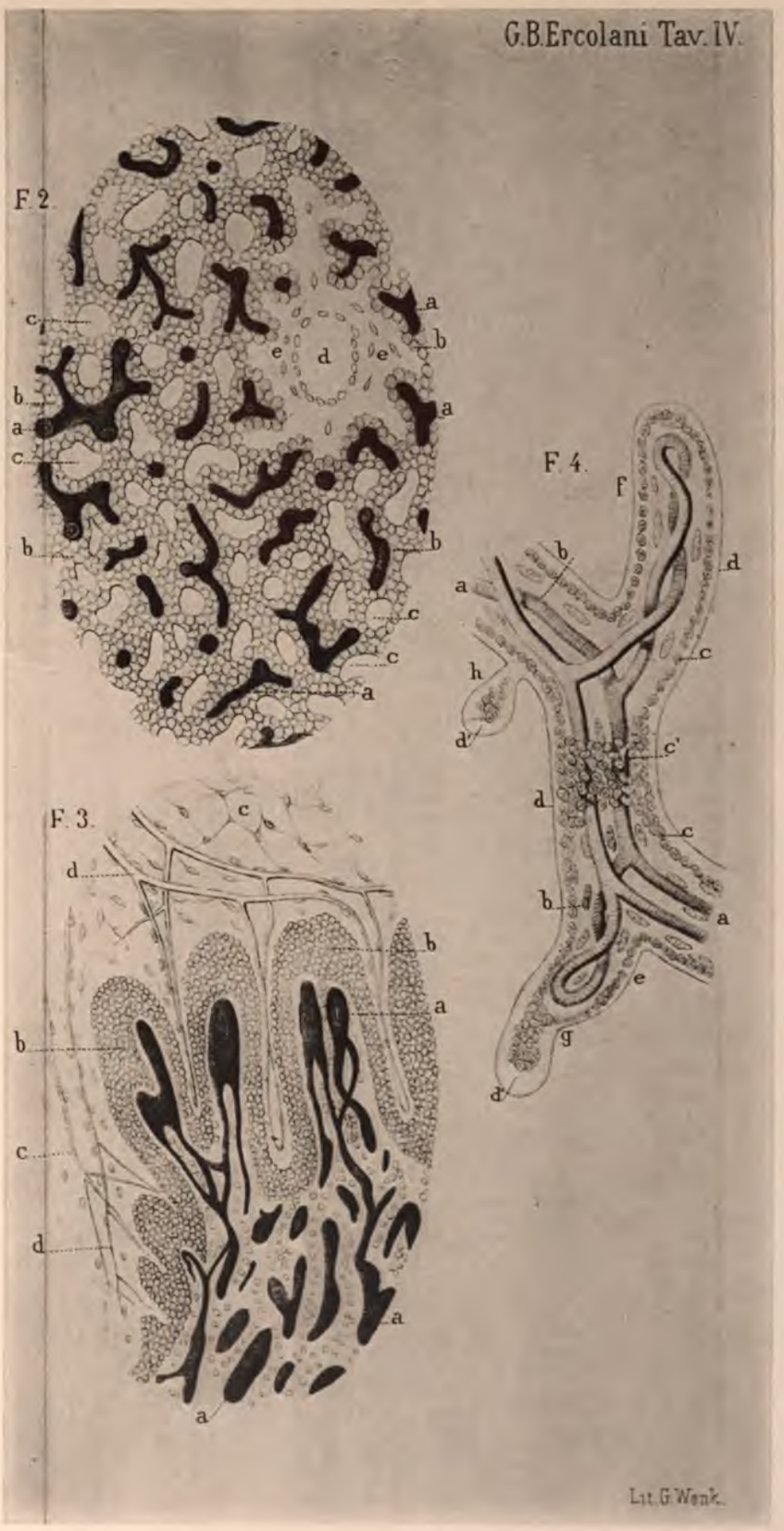
G.B.Ercolani Tav. IV.
F. 2.
F. 3.
F. 4.
Lit. G. Wenk.

F. 1.

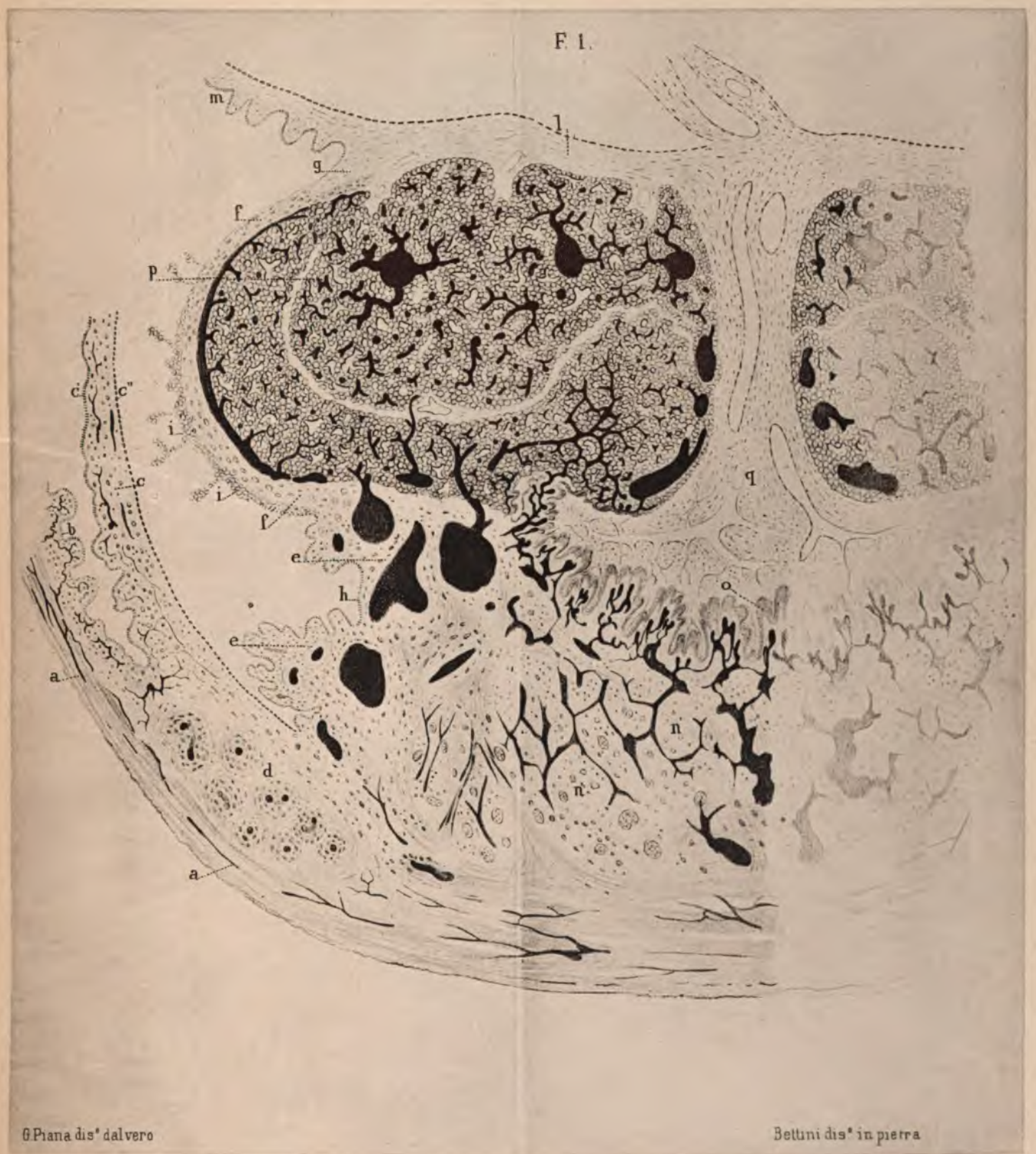

G. Piana dis.° dal vero

Bettini dis.° in pietra

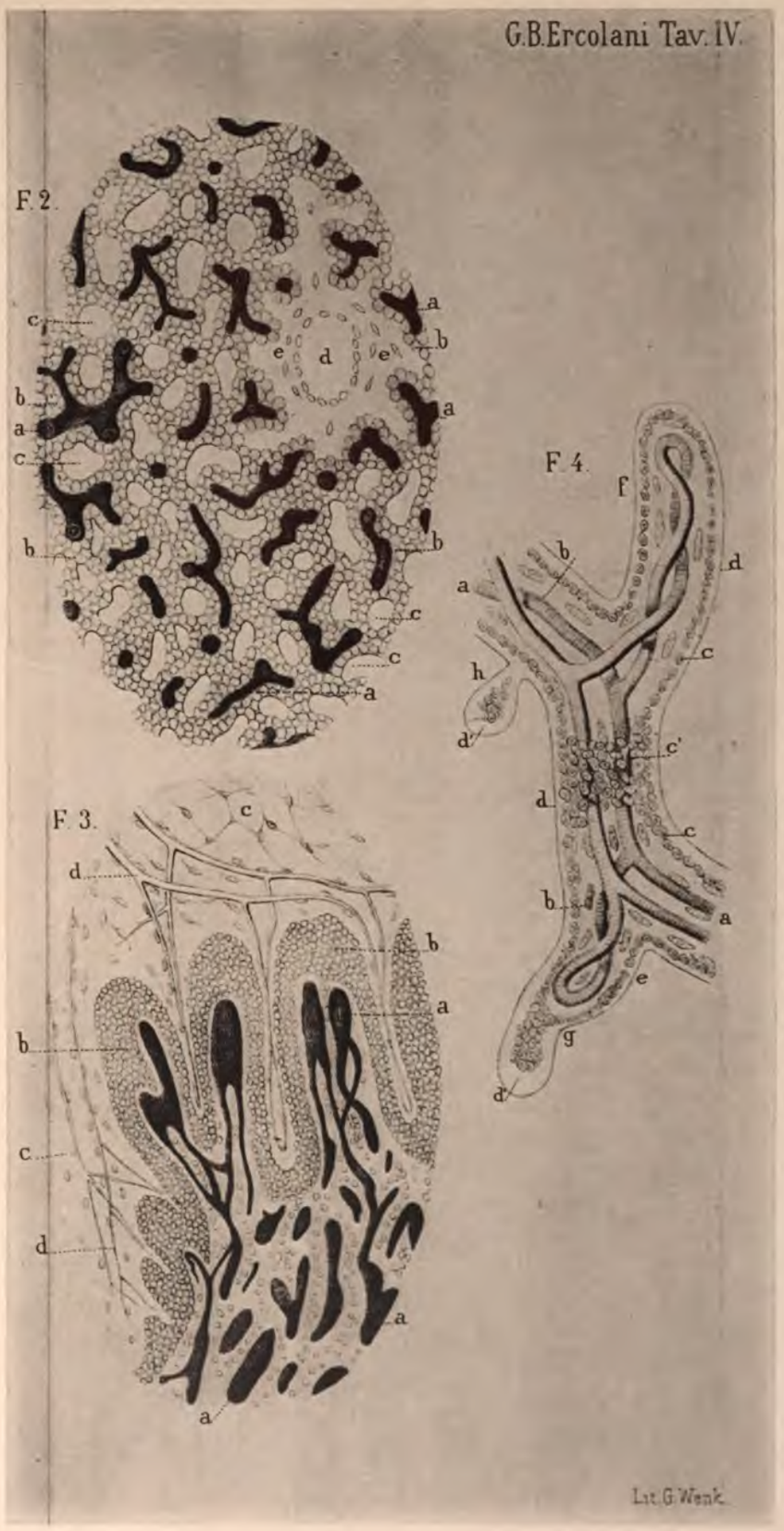
G.B.Ercolani Tav. IV.
F. 2.
F. 3.
F. 4.
Lit. G. Wenk.

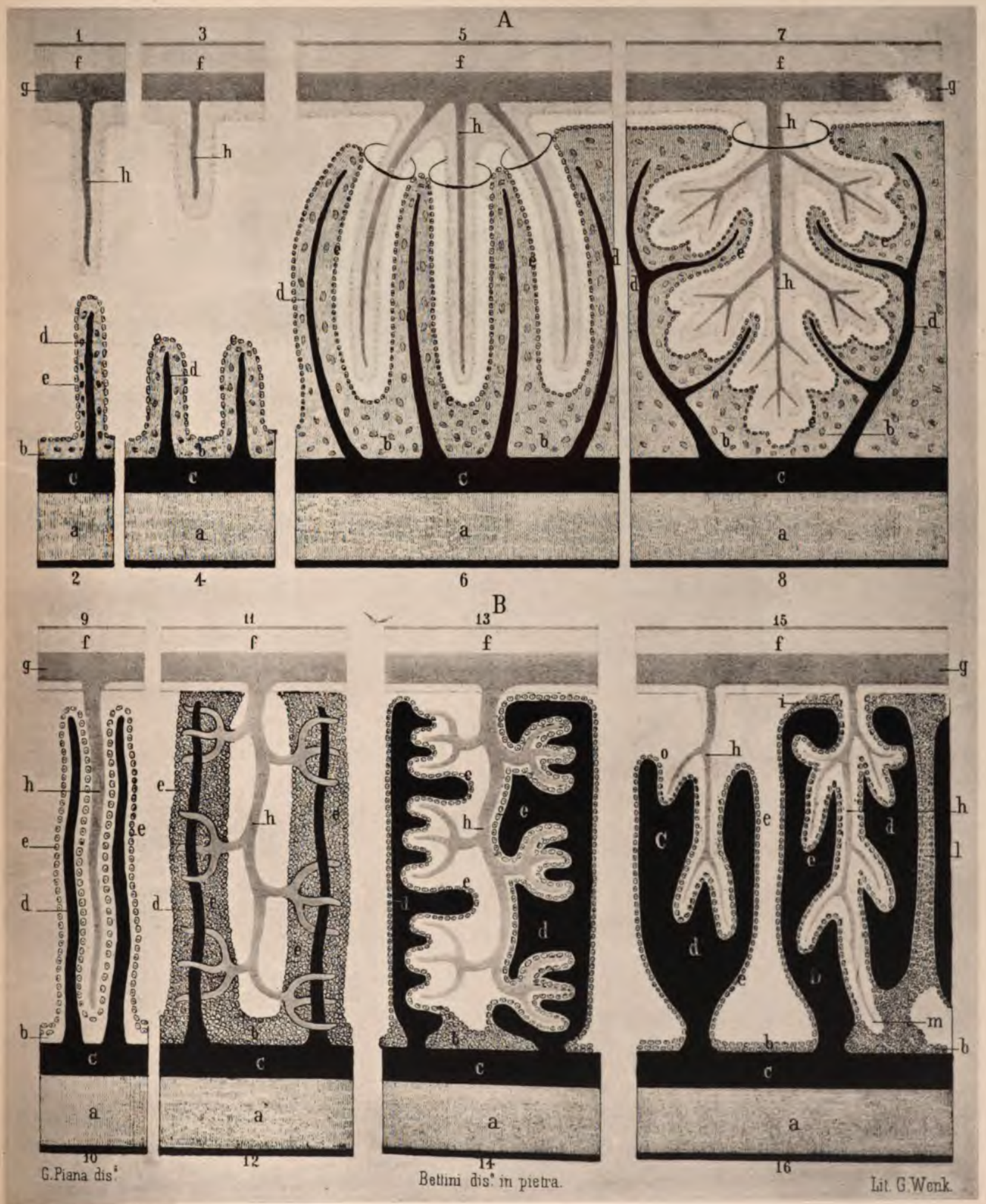

G.Piana dis.ª

Bettini dis.ª in pietra.

Lit. G.Wenk.